

# CONGENITAL CARDIOLOGY TODAY

Timely News and Information for BC/BE Congenital/Structural Cardiologists and Surgeons

Volume 7 / Issue 5

May 2009

International Edition

## IN THIS ISSUE

### Perinatal Circulatory Physiology: Its Influence on Clinical Manifestations of Neonatal Heart Disease: Part II

by P. Syamasundar Rao, MD  
~Page 1

### Using the Hybrid Approach in the Correction of Congenital and Structural Heart Disease

by Ziyad M. Hijazi, MD, MPH  
~Page 12

## DEPARTMENTS

### June Medical Meeting Focus - PICS ~AICS 2009

~Page 9

### Medical News, Products & Information

~Page 10

## CONGENITAL CARDIOLOGY TODAY

### Editorial and Subscription Offices

16 Cove Rd, Ste. 200  
Westerly, RI 02891 USA  
[www.CongenitalCardiologyToday.com](http://www.CongenitalCardiologyToday.com)

© 2009 by Congenital Cardiology Today ISSN: 1544-7787 (print); 1544-0499 (online). Published monthly. All rights reserved.

Statements or opinions expressed in Congenital Cardiology Today reflect the views of the authors and sponsors, and are not necessarily the views of Congenital Cardiology Today.

ASE 2009  
June 6-10, 2009  
Washington, DC, USA  
[www.asescientificsessions.org](http://www.asescientificsessions.org)

5th World Congress of Paediatric Cardiology and Cardiac Surgery  
June 22-26, 2009  
Cairns, Queensland, Australia  
[www.pccs2009.com](http://www.pccs2009.com)

## Perinatal Circulatory Physiology: Its Influence on Clinical Manifestations of Neonatal Heart Disease: Part II

By P. Syamasundar Rao, MD

### INTRODUCTION

In the last issue of Congenital Cardiology Today<sup>1</sup> the course of the fetal circulation, mechanisms that maintain fetal circulatory pathways, distribution of the cardiac output, fetal myocardial function and postnatal circulatory changes were addressed. In this second part, the influence of postnatal circulatory changes on the presentation of important congenital cardiac defects, as well as their therapeutic implications will be discussed.

Congenital heart disease is usually well-tolerated during fetal life. However, circulatory changes following birth have a marked effect on the clinical presentation and on the course of the heart disease in the early newborn period.

### DUCTUS ARTERIOSUS

The ductus arteriosus is a tubular muscular structure connecting the pulmonary artery with the descending aorta. The ductus diverts the desaturated blood from the pulmonary artery into the descending aorta and from there into the placenta for oxygenation. It is kept open during fetal life by locally produced and circulating prostaglandins. After the infant is born, the ductus arteriosus constricts and closes spontaneously, presumably secondary to increased PO<sub>2</sub> as well as to decreasing responsiveness of the ductal musculature to prostaglandins with increasing age. The importance of the ductus in various congenital heart defects will be reviewed.

### Hypoplastic Left Heart Syndrome (HLHS)

In HLHS, the mitral valve, left ventricle and/or the ascending aorta are markedly stenotic or atretic, and there is no forward flow from the left heart into the body.<sup>2,3</sup> The entire systemic circulation depends upon the flow through the patent ductus arteriosus (Figure 1). Following birth, as the PO<sub>2</sub> increases, the

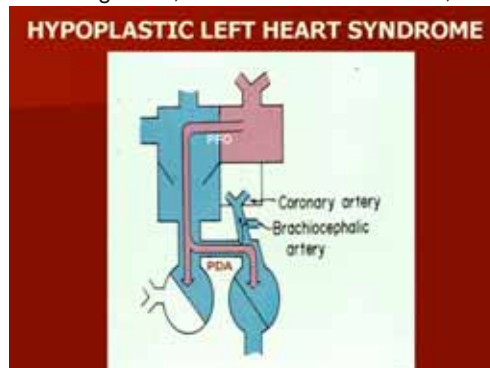


Figure 1. Box diagram of Hypoplastic Left Heart Syndrome. Because there is no forward flow from the left heart into the hypoplastic aorta, the systemic perfusion is dependent upon the patent ductus arteriosus (PDA). Retrograde flow into the brachio-cephalic vessels and coronary arteries is also shown. If the ductus constricts the systemic, perfusion is compromised. The pulmonary venous return cannot exit into the left ventricle, and its egress has to be into the right atrium via the patent foramen ovale (PFO). If the foramen ovale is obstructive, the infant will develop signs of pulmonary venous obstruction.

**Do you or your colleagues have interesting research results, observations, human interest stories, reports of meetings, etc. that you would like to share with the Congenital Cardiology community?**

Submit a brief summary of your proposed article to: [RichardK@CCT.bz](mailto:RichardK@CCT.bz)

The final manuscript may be between 400-4,000 words, contain pictures, graphs, charts and tables.

# INVOS

## REVEALING BRIGHTER FUTURES

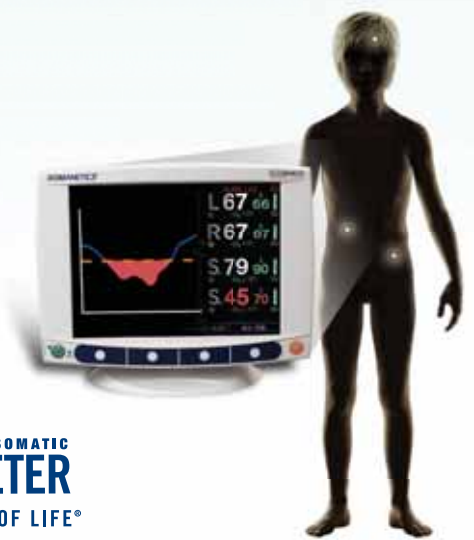
# SYSTEM



Someday I want to be a doctor, not a patient.

### His heart surgery seemed to go smoothly. But will kindergarten?

Brain dysoxygenation. Shock. Renal failure. Congenital heart patients face numerous ischemic threats, but the INVOS® System can help keep them safe. Oxygenation data from up to four perfusion distributic in real time, allowing rapid response. It also responds to intervene can better judge the impact and efficacy. let the INVOS System help these kids navigate through the OR and PICU... and perhaps even kindergarten too<sup>1-3</sup>.



**INVOS** CEREBRAL/SOMATIC  
**OXIMETER**  
REFLECTING THE COLOR OF LIFE®

1. Hoffman et al, Anesthesiology 2008; 109 A7 2. Dent et al, J Thorac Cardiovasc Surg. 2006 Jan;131(1):190-7  
3. Andropoulos et al, Anesthesiology 2007; 107: A209

**SOMANETICS®**

800-359-7662

Come visit our new expanded website at [www.somanetics.com](http://www.somanetics.com)

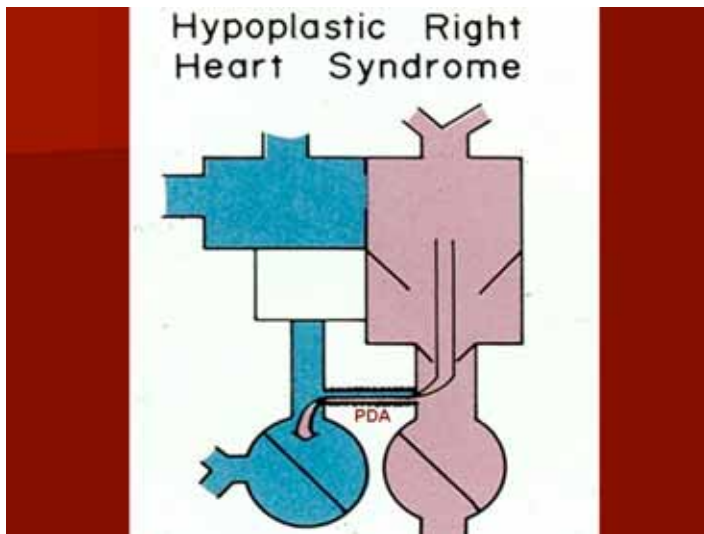


Figure 2. Box diagram of hypoplastic right heart syndrome. Since there is no forward flow into the pulmonary artery from the right ventricle, the pulmonary flow is dependent upon the patent ductus arteriosus (PDA). As the ductus begins to constrict, the pulmonary blood flow will decrease causing severe hypoxemia.

ductus arteriosus constricts and compromises the systemic blood flow. There is concurrent decrease in the pulmonary vascular resistance, again due in part to an increase in  $PO_2$ . This will result in a marked increase in pulmonary blood flow. A combination of these events causes severe acidemia (secondary to decreased systemic perfusion) and increase in arterial  $PO_2$  (related to increased pulmonary-to-systemic flow ratio). If untreated, severe congestive heart failure and death will result.

It seems logical not to increase  $PO_2$  by not increasing ambient oxygen concentration so as not to hasten the ductal closure. Administration of prostaglandin  $E_1$  will help keep the ductus patent, thus maintaining systemic perfusion. To further facilitate systemic perfusion through the ductus arteriosus, resistance to flow into the lungs should be increased. Lower  $FIO_2$  than room air is advocated so as to increase pulmonary vasoconstriction.

**Pulmonary Atresia with Intact Ventricular Septum**

Pulmonary atresia with intact ventricular septum is a complex cyanotic congenital heart defect characterized by complete obstruction of the pulmonary valve, two distinct ventricles, a patent tricuspid valve and no ventricular septal defect.<sup>4</sup> The right ventricle is usually, but not invariably, small and hypoplastic. Since there is complete blockage of the pulmonary valve, the pulmonary blood flow is entirely dependent upon the patency of the ductus (Figure 2). Initially (at birth) the ductus is patent and the pulmonary blood flow may be adequate with

| Table 1A & 1B. Ductal-Dependent Cardiac Defects |   |
|---|---|
| <b>A. Ductal-Dependent Pulmonary Flow</b>       | <ul style="list-style-type: none"> <li>• Pulmonary atresia or critical stenosis with intact ventricular septum</li> <li>• Pulmonary atresia with ventricular septal defect</li> <li>• Severe tetralogy of Fallot</li> <li>• Tricuspid atresia</li> <li>• Complex cyanotic heart disease with pulmonary atresia or severe stenosis</li> <li>• Ebstein's anomaly of the tricuspid valve</li> <li>• Hypoplastic right ventricle</li> </ul> |
| <b>B. Ductal-Dependent Systemic Flow</b>        | <ul style="list-style-type: none"> <li>• Hypoplastic left heart syndrome</li> <li>• Severe coarctation of the aorta syndrome</li> <li>• Interrupted aortic arch</li> </ul>  |

reasonable arterial  $PO_2$ . However, as the ductus begins to close during the natural process of closure, marked hypoxemia and metabolic acidosis will ensue. Prostaglandin  $E_1$  infusion usually helps to keep the ductus open. Several other cardiac defects (Table 1A) with severe stenosis or atresia of the pulmonary outflow tract are similarly ductal dependent and are benefited by prostaglandin  $E_1$  infusion.

**Total Anomalous Pulmonary Venous Connection (TAPVC)**

In TAPVC, the pulmonary veins drain into the right atrium or systemic veins. In the infra-diaphragmatic type of TAPVC, pulmonary venous obstruction is present with resultant pulmonary edema and marked increase in the pulmonary arterial pressures and resistance. If the ductus is open, decompression of pulmonary arterial tree may occur with some relief of supra-systemic pulmonary pressures although this is at the expense of deoxygenated blood bypassing the lungs.

**Transposition of the Great Arteries (TGA)**

In TGA the aorta arises from the right ventricle and the pulmonary artery from the left ventricle. Consequently the pulmonary and systemic circulations are parallel (Figure 3), in contradistinction to normal, in series arrangement. If there is no inter-circulatory mixing across a patent foramen ovale or patent ductus arteriosus, the infant would not survive because there is no delivery of oxygenated blood to the body. An open ductus may enhance inter-circulatory mixing, thus improving arterial  $PO_2$ .  $PGE_1$  infusion is helpful in abating hypoxemia in some patients with TGA.

**Coarctation of the Aorta**



For information, please call 1-800-BRAUN2 (227-2862)

[www.bbraunusa.com](http://www.bbraunusa.com)



Working Together to Develop a Better Tomorrow

Development of coarctation of the aorta is at least in part related to posterior shelf-like structure within folding of medial and intimal tissue of the aortic wall and in part the result of constriction of the ductus arteriosus.<sup>5,6</sup> Blood flow from the proximal part of the aorta into the descending aorta around the posterior shelf of coarctation is facilitated by a patent ductus (Figure 4A). This bypass mechanism is no longer available when the ductus closes (Figure 4B). Acute aortic obstruction develops rapidly with consequent development of symptoms. Temporary relief can be obtained by prostaglandin E<sub>1</sub> infusion.

**Interrupted Aortic Arch**

This is an uncommon defect with complete lack of communication between the ascending and descending aorta; this interruption may occur at various levels. Irrespective of the level of obstruction, the blood flow goes from the pulmonary artery to the descending aorta via a ductus arteriosus, perfusing the lower part of the body. Again, during the normal course of maturation, the ductus tends to close, causing no perfusion to the lower part of the body. Prostaglandin E<sub>1</sub> infusion opens the ductus, restoring circulation to the lower part of the body.

**DUCTUS VENOSUS**

The ductus venosus connects the umbilical vein to the inferior vena cava. In the fetus a substantial portion of umbilical venous blood goes through this channel and is presumed to be kept open by the mechanical effect of the blood flowing through it. Following birth, it closes spontaneously because of lack of flow through it, although the mechanisms of closure may be similar to ductus arteriosus, alluded to above.

**TAPVC**

In infra-diaphragmatic type of TAPVC, some of the pulmonary venous flow will be through the ductus venosus. When the ductus venosus closes, pulmonary venous flow gets obstructed and the infant becomes symptomatic with tachypnea, cyanosis and pulmonary edema because of the necessity of the blood to pass through the liver. This is secondary to high impedance to the passage of blood through the hepatic circulation.

**FORAMEN OVALE**

The foramen ovale is an opening in the atrial septum formed by the septum secundum above and septum primum below and is kept patent in the fetus because of the mechanical effect of streaming of the inferior vena caval blood into the left atrium. At birth a combination of increase in the left atrial pressure secondary to increased pulmonary venous return and decrease in the right atrial pressure secondary to decreased placental return will result in apposition of the septum primum and septum secundum causing functional closure of foramen ovale. The role

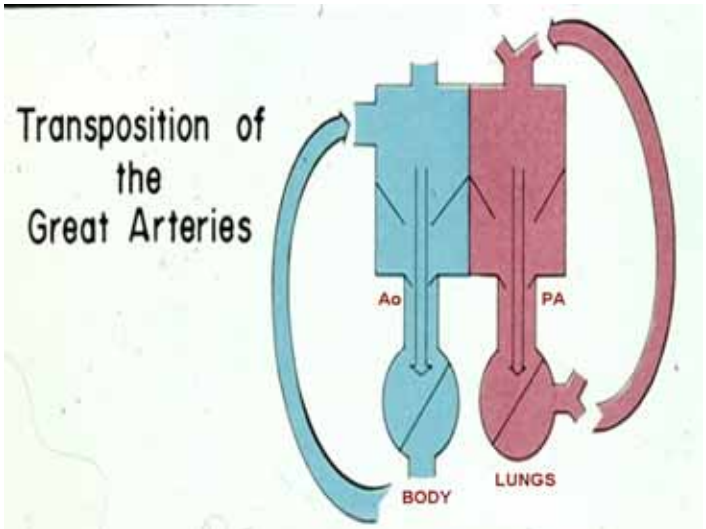


Figure 3. Box diagram of the heart showing parallel circulations in transposition of the great arteries. Note that right ventricle pumps into the aorta (Ao) (because of transposition) which goes to the body and returns into right atrium and back into the body. Similarly left ventricular output goes to the pulmonary artery (PA) and lungs and returns back to the left atrium and left ventricle to be pumped back into the lungs. Unless there are inter-circulatory communications via either a patent foramen ovale or patent ductus arteriosus, the infant cannot survive. Mixing across a ventricular septal defect (VSD) if such is present (not shown in the diagram), would also prevent progressive hypoxemia and death.

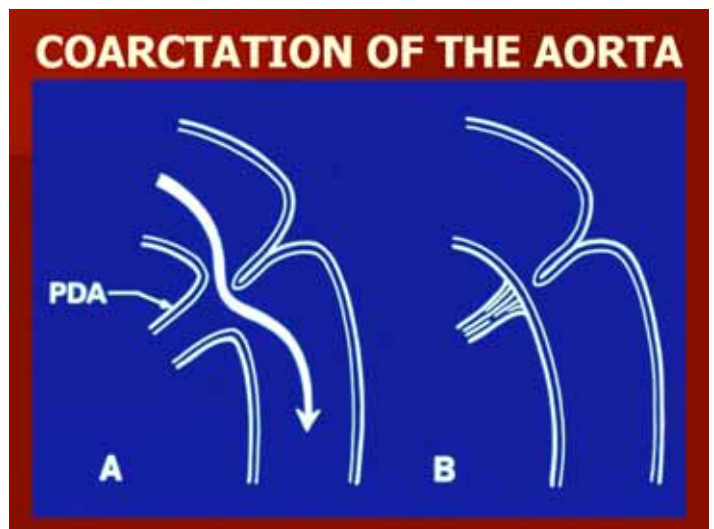


Figure 4. Diagrammatic portrayal of the flow from the aortic isthmus to the descending aorta in coarctation of the aorta: A, with open ductus (PDA), and B, with closed ductus. See the text for discussion.

case reviews in

**pda**



*free on-demand webcast*

specifically designed for clinicians treating patients with **patent ductus arteriosus**

[www.5StarMedEd.org/pda-cases](http://www.5StarMedEd.org/pda-cases)

of patency of the foramen ovale in congenital heart defects in the neonate will be discussed.

**Right-sided Obstructive Lesions**

In defects such as tricuspid or pulmonary atresia, because of atretic pulmonary and/or tricuspid valve, there is no forward flow into the pulmonary circuit. The blood regurgitates back into the right atrium. The right atrial pressure is higher than that in the left atrium; this will keep the foramen ovale open. Therefore, an obligatory right-to-left shunt occurs across the atrial septum (Figures 4). Indeed, right-to-left shunting at the atrial level is essential for survival of the patient. While rare in neonatal period, the foramen ovale can become restrictive and may need enlargement either by transcatheter or surgical methodology.<sup>7</sup>

**TAPVC**

In TAPVC the entire pulmonary venous return comes into the right atrium or into systemic veins. From there its gets distributed into the right and left heart structures. Consequently the systemic blood flow depends upon the patency of the foramen ovale. All the systemic output must pass through the patent foramen ovale. While obstruction at the foramen level can occur, it is more often than not located at other sites. Should it be the sole obstruction, temporary relief can be provided by septostomy.<sup>7</sup>

**Left-sided Obstruction Lesions**

In HLHS and mitral or aortic atresia, the pulmonary venous return coming into the left atrium can't empty into the left ventricle and therefore has to be shunted into the right atrium. Consequently, the foramen ovale has to remain open in order to direct the pulmonary venous return into the right heart (Figure 1). Should the foramen ovale close, surgical or balloon atrial septostomy should be performed to relieve the interatrial obstruction.<sup>7</sup>

**Transposition of the Great Arteries**

As alluded to above, in TGA the circulation is parallel and some inter-circulatory mixing is essential for survival. If the fetal circulatory pathways close, as they usually do, creation of or enlargement of atrial septal defect (Figure 6) by balloon atrial septostomy is mandatory. Such an atrial communication may sometimes be necessary even in patients with a naturally open or prostaglandin-induced patency of the ductus arteriosus.

**Left-to-right shunt lesions**

In lesions such as large patent ductus arteriosus (PDA) and ventricular septal defect (VSD), the pulmonary blood flow is markedly increased (see Pulmonary Vascular Bed section below) and consequently the left atrial size increases. This left atrial enlargement may cause stretching of the patent foramen ovale resulting in an additional left-to-right atrial shunting. However, such shunting maintains low pulmonary venous pressure and may even prevent pulmonary edema.

**PULMONARY VASCULAR BED**

In utero, the pulmonary vascular resistance is high, most likely due to the low PO<sub>2</sub> to which the pulmonary arterioles are exposed.<sup>1</sup> Following birth, normal breathing and oxygenation of

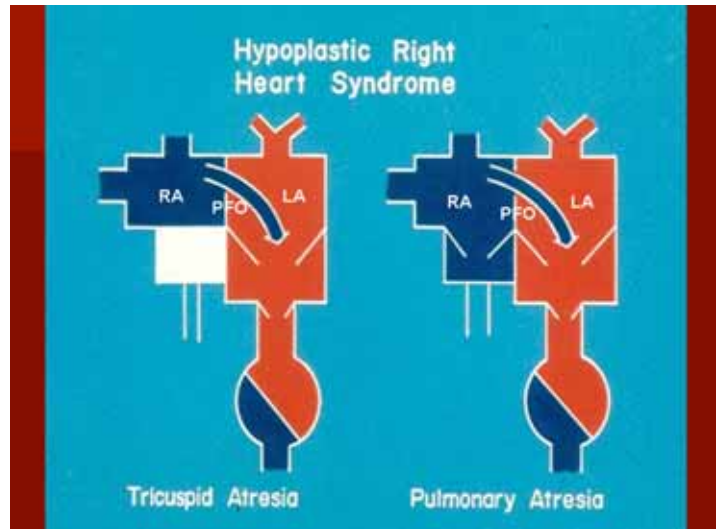


Figure 5. Box diagrams of hypoplastic right heart syndromes. In pulmonary atresia (or tricuspid atresia) the right atrial (RA) blood has to egress into the left atrium (LA) via the patent foramen ovale (PFO). If the PFO is obstructive, signs of systemic venous obstruction will develop.

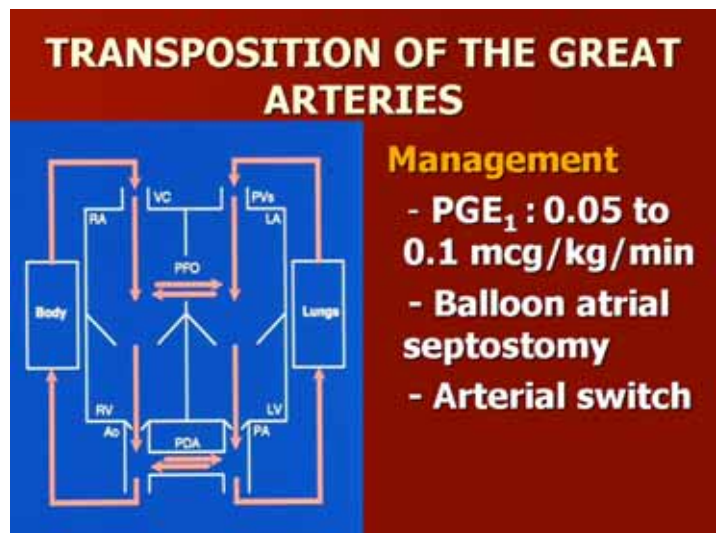


Figure 6. Box diagram of the heart showing parallel circulations in transposition of the great arteries. Note that right ventricle (RV) pumps into the aorta (because of transposition) which goes to the body and returns into right atrium and back into the body. Similarly left ventricular output goes to the pulmonary artery and lungs and returns back to the left atrium and left ventricle to be pumped back into the lungs. Unless there are inter-circulatory communications via either a patent foramen ovale (PFO) or patent ductus arteriosus (PDA), the infant cannot survive. Mixing across a ventricular septal defect (VSD) if such is present (not shown in the diagram) would also prevent progressive hypoxemia and death. PGE<sub>1</sub> infusion to open the ductus and balloon septostomy to enlarge the PFO are usually helpful.

the lungs take place resulting in the fall of pulmonary vascular resistance and pressure. The influence of pulmonary vascular changes in the neonate will be reviewed.

**“Congenital heart disease is usually well-tolerated during fetal life. However, circulatory changes following birth have a marked effect on the clinical presentation and on the course of the heart disease in the early newborn period..”**

### Large Inter-Circulatory Connections

In the presence of a large systemic-to-pulmonary communication such as VSD, the pressures in both ventricles are similar. Therefore, the quantity of left-to-right shunt is to a great extent dependent upon the ratio of pulmonary to systemic vascular resistance. If the pulmonary vascular resistance decreases in a normal fashion within the first few hours to days, a large left-to-right shunt and congestive heart failure will develop during the first few days to weeks of life. However, this does not usually happen in otherwise normal babies until the age of 4 to 12 weeks. This is because of delayed regression of the pulmonary vascular resistance and pulmonary arteriolar muscular thickness. Increased pressure to which the pulmonary arterioles are subjected may be responsible for this delayed regression. However, the exact mechanism through which the high pressure acts to delay the normal involution of the pulmonary vasculature is not known.

Any cardiac defect with large inter-circulatory connection such as large patent ductus arteriosus, double outlet right ventricle, truncus arteriosus, single ventricle and others (all without associated pulmonary stenosis) affects the pulmonary vascular bed in a manner similar to that described for the VSD.

### Abnormal Development of Pulmonary Vasculature

The development of fetal pulmonary vasculature is dependent upon the  $PO_2$  to which it is exposed. Therefore, if the  $PO_2$  of pulmonary blood is increased because of a cardiac defect, pulmonary vasculature (arterioles) remains underdeveloped and less muscular. Consequently, the pulmonary vasculature may regress rapidly producing a decrease in the pulmonary vascular resistance and development of a large left-to-right shunt much earlier than anticipated.

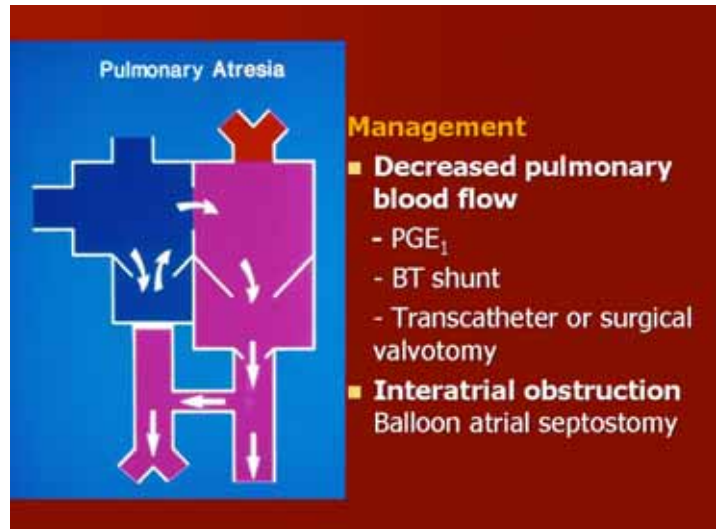


Figure 7. Box diagram of the heart showing pulmonary atresia with intact ventricular septum. Since there is no forward flow into the pulmonary artery from the right ventricle, the pulmonary flow is dependent upon the patent ductus arteriosus (PDA). Administration of  $PGE_1$  followed by transcatheter or surgical opening of the pulmonary valve or creation of an aorto-pulmonary shunt such as Blalock-Taussig (BT) shunt is usually performed. If interatrial obstruction develops, transcatheter or rarely surgical atrial septostomy may become necessary.

### Prematurity

In premature infants, because of lack of complete development of the media of the pulmonary arterioles, there is less pulmonary arteriolar smooth muscle to regress; therefore, the infants with large systemic-pulmonary communications develop heart failure much earlier than expected for normal full-term newborn. But, if they also have pulmonary disease producing hypoxia, a fall in pulmonary vascular resistance may be delayed and as the infant improves from lung disease, a large left-to-right shunt and congestive heart failure will develop.

### Other Factors

Chronic hypoxia also delays regression of pulmonary vasculature. Decreased ambient oxygen at high altitude and pulmonary disease may delay the development of large left-to-right shunt and congestive heart failure in patients with large inter-circulatory connections.

High left atrial pressure caused by left ventricular inflow obstructions (mitral stenosis/atresia and HLHS complexes) also

OPTIMIZING THE  
MANAGEMENT OF

pda

Join us for a free  
on-demand webcast

DEC 2008 – NOV 2009

[www.5StarMedEd.org/pda-management](http://www.5StarMedEd.org/pda-management)

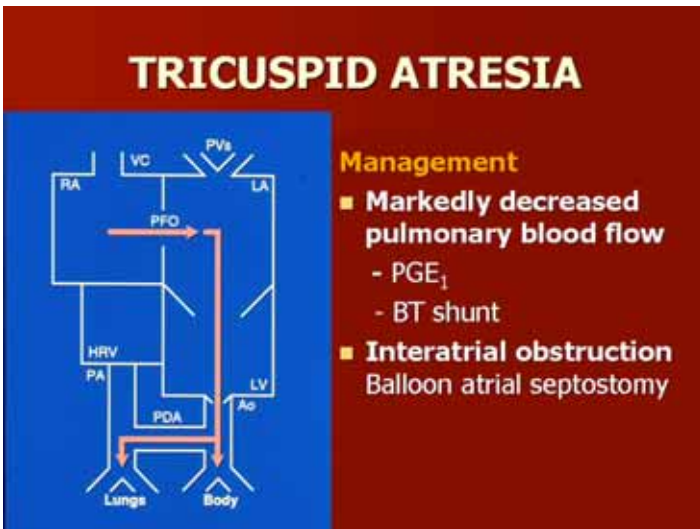


Figure 8. Box diagram of the heart showing tricuspid atresia. When there is associated pulmonary atresia or a very small ventricular septal defect, the pulmonary flow is dependent upon the patent ductus arteriosus (PDA). Administration of PGE<sub>1</sub> followed by an aorto-pulmonary shunt such as Blalock-Taussig (BT) shunt is usually performed. If interatrial obstruction develops, transcatheter or rarely surgical atrial septostomy may become necessary.

cause delayed involution of the pulmonary arterioles, although the mechanism by which this is affected is not understood.

**THERAPEUTIC IMPLICATIONS**

Therapeutic implications of post-natal circulatory changes in some cardiac defects will be reviewed.

**Transposition of the Great Arteries**

In TGA severe hypoxemia develops as the PDA and foramen ovale close. Initially prostaglandin E<sub>1</sub> infusion should be started to open the ductus (Figure 6) which may allow inter-circulatory mixing and improve hypoxemia. However, the degree of mixing may not be adequate to wait until the arterial switch procedure (Jatene) is performed. In such situations balloon atrial septostomy (Figure 6) should be performed.<sup>7</sup>

**Right-sided Obstructive Lesions**

In right heart obstructive lesions such as pulmonary atresia (Figure 7), tricuspid atresia (Figure 8) and severe tetralogy of Fallot (Figure 9), as the ductus begins to close the pulmonary blood flow decreases and hypoxemia develops. Administration of PGE<sub>1</sub> usually restores the pulmonary flow and improves hypoxemia. A more permanent solution to augment and maintain pulmonary blood flow should follow. This includes either transcatheter or surgical opening of the pulmonary valve or creation of an aorto-pulmonary shunt such as Blalock-Taussig (BT) shunt for pulmonary atresia (Figure 8), BT shunt for tricuspid atresia (Figure 9) and BT shunt, balloon pulmonary valvuloplasty,<sup>8</sup> or total surgical correction (depending upon the anatomy) for tetralogy of Fallot (Figure 10). A similar approach is used in other lesions associated with severe pulmonary stenosis or atresia (Table IA). An alternative to BT shunt is implantation of ductal stents.<sup>9</sup>

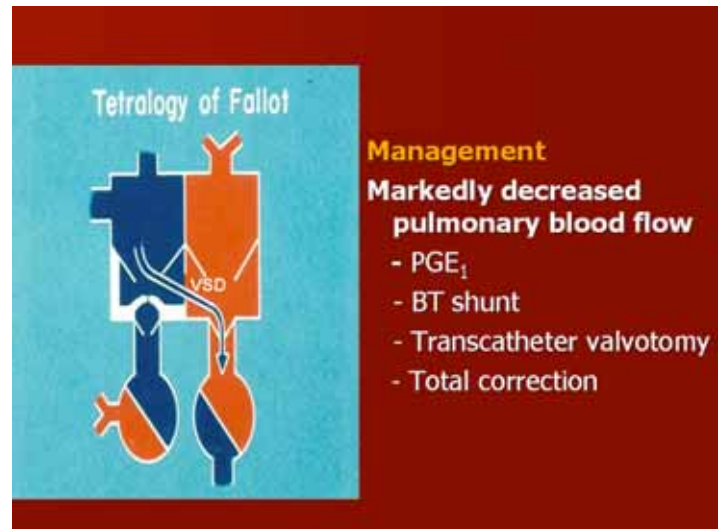

Figure 9. Box diagram of the heart showing tetralogy of Fallot demonstrating right to left shunt across the ventricular septal defect (VSD). When there is associated pulmonary atresia or a very severe pulmonary stenosis the pulmonary flow is dependent upon the patent ductus arteriosus. In some tetralogy patients neonatal intervention is needed. PGE<sub>1</sub> is initially administered to increase pulmonary blood flow and to improve hypoxemia. This is followed by BT shunt, balloon pulmonary valvuloplasty or total surgical correcting depending upon the anatomy.

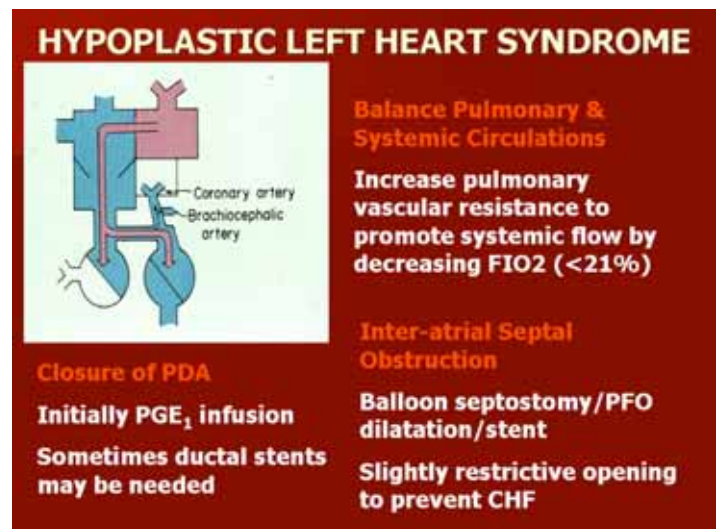


Figure 10. Box diagram of the heart showing hypoplastic left heart syndrome and possible therapeutic interventions.

Sometimes interatrial obstruction develops in patients with pulmonary and tricuspid atresia (Figures 8 and 9), and transcatheter or surgical atrial septostomy<sup>7</sup> may become necessary.

**Left-sided Obstruction Lesions**

In HLHS and mitral or aortic atresia (Figure 10), again the ductus tends to close spontaneously soon after birth. PGE<sub>1</sub> infusion to open the ductus is usually effective. Decrease in

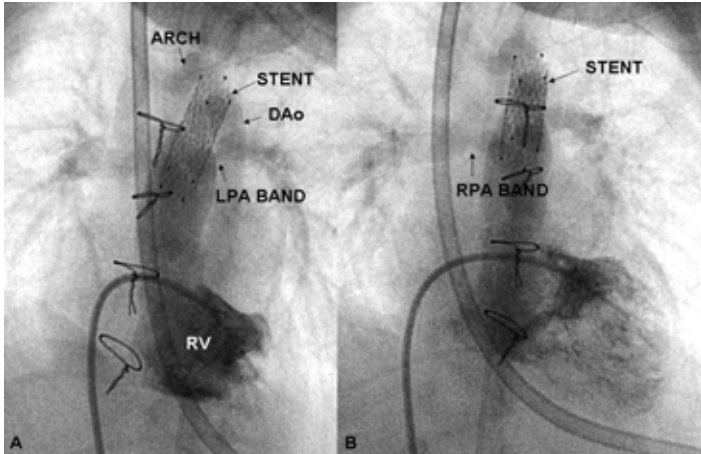


Figure 11. Selected right ventricular (RV) cine-angiographic frames demonstrating a ductal stent implanted during hybrid procedure. Note the opacification of the descending aorta (DAo) with concurrent opacification of the aortic arch (ARCH) by retrograde flow. The left pulmonary artery (LPA) band (arrow) is clearly seen. (A). Slightly different angle of cine projection is used (B) to demonstrate right pulmonary artery (RPA) band.

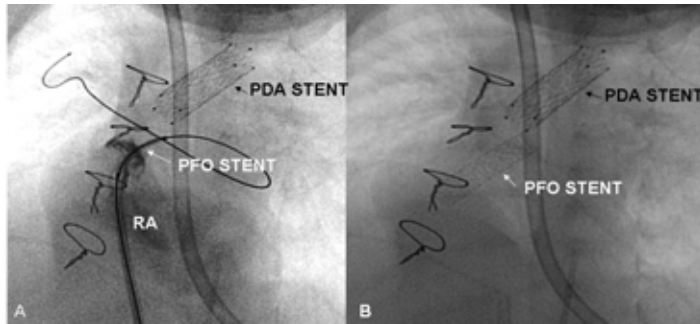


Figure 12. Selected cine frames demonstrating stent implantation (A) in the restrictive patent foramen ovale (PFO) and its position across the atrial septum (B) after deployment and removal of the balloon and guide wire.

pulmonary vascular resistance that follows lung expansion after birth increases flow into the lungs, thus compromising systemic flow. This can in part be reversed by lowering  $\text{FIO}_2$  to less than room air (to increase pulmonary vasoconstriction), thus facilitating systemic perfusion through the ductus arteriosus. Maintaining some restriction at the level of patent foramen ovale will also help prevent rapid fall in pulmonary resistance. These treatment modalities may tide over the patient until the conventional Norwood procedure is performed.

Sometimes severe inter-atrial obstruction may develop and may have to be relieved by atrial septostomy.<sup>7</sup>

Utilizing these principles, hybrid procedures have been developed<sup>10</sup> in which the pulmonary artery bands are placed surgically, constricting both branch pulmonary arteries and a stent implanted within the ductus arteriosus (Figure 11) via a sheath placed in the main pulmonary artery at the time of banding. Some of these infants may develop severe restriction of the atrial septum, requiring placement of a stent in the patent foramen ovale (Figure 12).

### Coarctation of the Aorta and Interrupted Aortic Arch

In both these conditions, closure of ductus causes severe decrease in perfusion to the lower part of the body (Table IB) and can be relieved by prostaglandin infusion. This should be followed by surgical correction.

### TAPVC

In some patients with TAPVC, spontaneous closure of ductus venosus and ductus arteriosus and restriction of foramen ovale may have therapeutic implication. However, in the majority of patients with infra-diaphragmatic type of TAPVC, the major issue is pulmonary venous obstruction, requiring emergent surgical correction.

### VSD

In large ventricular defects, because of high pulmonary resistance at birth, the murmur of VSD may not be heard at birth; the murmur becomes manifest in a few weeks after birth. The babies also do not usually go into heart failure at birth. Congestive heart failure does not become apparent until six to eight weeks of age because of delayed involution of pulmonary arterioles.

Exactly the same physiological principles may be applied to patients with other large inter-circulatory communications such as a large PDA and other complex heart defects such as: double-outlet right ventricle, double inlet left ventricle, transposition of the great arteries with a large VSD, tricuspid atresia with a large VSD and truncus arteriosus, all without associated pulmonary stenosis.

High pulmonary resistance secondary to hypoxemia or recurrent aspiration (tracheo-esophageal fistula) prevents development of a large left-to-right shunt and development of congestive heart failure. When a baby's lung disease gets better, sudden onset of congestive heart failure occurs.

In small VSDs, the murmur of the defect may be heard at birth since the normal fall in pulmonary vascular resistance is not interfered with.

### Ebstein's Anomaly of the Tricuspid Valve

In severe forms of Ebstein's, right-to-left shunt at atrial level is increased by high neonatal pulmonary vascular resistance. As the pulmonary vascular resistance falls, the degree of right-to-left atrial may diminish, improving the hypoxemia.

In some patients, administration of  $\text{PGE}_1$  is helpful in augmenting pulmonary flow, especially in association with pulmonary valve stenosis or atresia.

### SUMMARY AND CONCLUSIONS

Postnatal circulatory changes markedly influence the clinical presentation and clinical course of the neonate with congenital heart defects. Closure of the ductus arteriosus adversely affects:

1. The systemic perfusion in HLHS and aortic arch obstructions,



**“Postnatal circulatory changes markedly influence the clinical presentation and clinical course of the neonate with congenital heart defects. heart disease in the early newborn.”**

2. Pulmonary blood flow in cardiac defects with severe pulmonary stenosis or atresia and 3. Inter-circulatory mixing in TGA.

Prostaglandin E<sub>1</sub> infusion is effective in re-opening the ductus or maintaining its patency. Longer lasting solutions include BT shunts and ductal stents.

Spontaneous closure or restriction of foramen ovale adversely affects:

1. Right-to-left shunting in right heart obstructive lesions and TAPVC,
2. Left-to-right shunting in left heart obstructive lesions and
3. Inter-circulatory mixing in TGA.

When the foramen ovale is restrictive, transcatheter or surgical septostomy is beneficial.

Pulmonary vascular resistance plays a critical role in patients with large inter-circulatory communications.

**REFERENCES**

1. Rao PS. Perinatal circulatory physiology: its influence on clinical manifestations of neonatal heart disease: Part I. *Congenital Cardiology Today* 2008; 7(4): 1-9.
2. Rao PS, Striepe V, Merrill WM. Hypoplastic left heart syndrome. In: Kambam J (Ed), *Cardiac Anesthesia for Infants and Children*. St. Louis, Mosby, 1993, pp. 299-309.

3. Rao PS, Turner R, Forbes TJ. Hypoplastic left heart syndrome. In e-medicine – Pediatrics <http://www.emedicine.com>.
4. Rao PS. Pulmonary atresia with intact ventricular septum. *Current Treatment Options Cardiovasc Med* 2002; 4: 321-36.
5. Rao PS. Coarctation of the aorta. In: *Secondary Forms of Hypertension*, Ram CVS (ed), *Seminars in Nephrology*, Kurtzman NA (ed), W.B. Saunders, Philadelphia, PA 1995; 15(2):81-105.
6. Rao PS. Coarctation of the aorta. In e-medicine – Pediatrics <http://www.emedicine.com>.
7. Rao PS. Role of interventional cardiology in neonates: part I. non-surgical atrial septostomy. *Neonatology Today* 2007; 2(9): 9-14.
8. Rao PS. Role of interventional cardiology in neonates: Part II - Balloon angioplasty/ valvuloplasty. *Neonatology Today* 2007; 2(10): 1-12.
9. Rao PS. Role of interventional cardiology in the treatment of neonates: Part III. *Neonatology Today* 2007; 2(11): 1-10.
10. Galantowicz M, Cheatham JP. Lessons learned from the development of a new hybrid strategy for the management of hypoplastic left heart syndrome. *Pediatr Cardiol*. 2005; 26:190-9.

**CCT**

*P. Syamasundar Rao, MD  
Professor and Division Director,  
Department of Pediatric Cardiology  
Division of Pulmonary and Critical  
Care Medicine  
University of Texas - Houston Medical  
School  
6431 Fannin St., MSB 3.132  
Houston, TX 77030 USA  
Phone: 713-500-5738  
Fax: 713-500-0653*

*P.Syamasundar.Rao@uth.tmc.edu*

**JUNE MEDICAL MEETING FOCUS**

**PEDIATRIC & ADULT INTERVENTIONAL CARDIAC SYMPOSIUM - PICS / AICS 2009**  
*With Live Case Demonstrations*  
June 21-23, 2009; Cairns, Australia  
[www.picsymposium.com/](http://www.picsymposium.com/)

The PICS Foundation in Collaboration with the World Congress of Paediatric Cardiology & Cardiac Surgery

**Course Directors:** Drs. Ziyad M. Hijazi, William Hellenbrand, John P. Cheatham, Carlos Pedra, Geoffrey K. Lane, Zahid Amin (Course Co-Director)

**Focus on the Latest Advances in Interventional Therapies for Children and Adults** with congenital and structural heart disease, including the latest technologies in devices, implantable valves, stents and balloons. Special sessions will provide an in-depth focus on septal defect closure, coarctation stenting, embolization therapies, emerging new imaging modalities for cardiac intervention, and hybrid intervention for HLHS.

**Breakout Sessions** for all professionals who work in pediatric and adult cardiology, the catheterization lab and operating room.


**Debates** between cardiologists and surgeons on controversial issues on intervention for congenital and structural heart disease.

**“My Nightmare Cases in the Cath Lab”**

**Live Case Demonstrations** from multiple international venues featuring approved and non-approved devices will be transmitted daily from many cardiac centers around the world. Attendees will have the opportunity to interact directly with the operators to discuss the management options for these cases.

**Abstracts** - Interventional abstracts will be presented.

*This event is approved for up to 30 credits by the Centre for Continuing Medical Education (“CME”). The Centre for CME, Faculty of Medicine, McGill University is fully accredited by the Committee on Accreditation of Canadian Medical Schools and through the (CACMS) is accredited to award AMA PRA category 1 credits.*



**ASE 2009**

**20<sup>th</sup> Annual Scientific Sessions**  
*June 6-10 • Washington, DC*

**Dedicated  
Congenital Track!**

# Using the Hybrid Approach in the Correction of Congenital and Structural Heart Disease

By Ziyad M. Hijazi, MD, MPH

As one of the top five medical centers in the US, Rush University Medical Center in Chicago opened the Rush Center for Congenital and Structural Heart Disease to address the needs of patients born with heart abnormalities and adults suffering from structural heart defects. Rush brings together a distinguished team of cardiac specialists, including interventional cardiologists, electrophysiologists, transplant cardiologists, echocardiologists and cardiovascular surgeons, along with state-of-the-art X-ray vascular technology to handle the most complex cases and provide the best care possible.

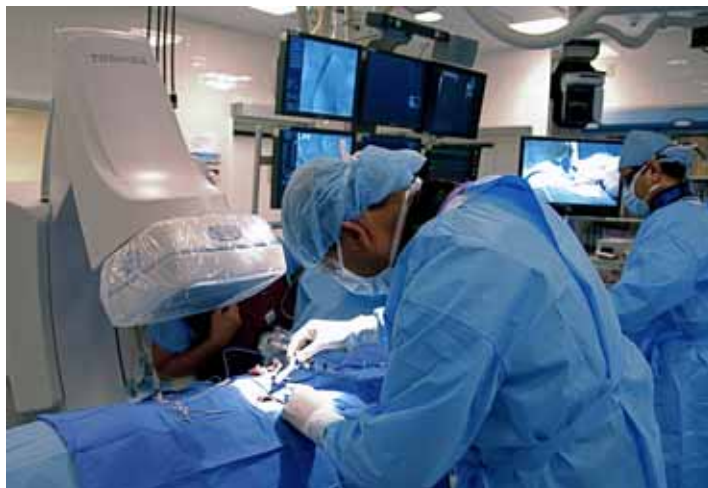
As a pioneer in the non-surgical correction of congenital heart defects, I was recruited by Rush University to help shape the vision and methodology of Rush Center for Congenital and Structural Heart Disease and to practice the innovative “hybrid” approach to treating patients with heart defects, including infants and adults with congenital and structural heart conditions, ranging from asymptomatic to life-threatening. At the time the Rush Center opened, it was one of only three places in the country employing this type of innovative hybrid approach to treating heart disease. It is still one of the most experienced centers in hybrid cardiovascular intervention today.

In this article, I address using the hybrid approach for the correction of congenital and structural heart disease, common hybrid procedures including Hypoplastic Left Heart Syndrome (HLHS), and factors to consider when building a hybrid operating room (OR) suite.

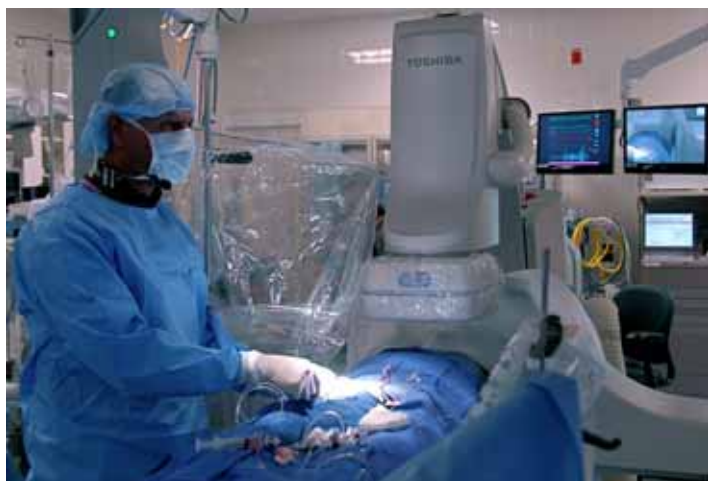## Defining The Hybrid Approach

The hybrid approach brings interventional cardiologists, like myself, along with cardiovascular surgeons and other clinical experts together in the operating room (OR) to offer a complete, collaborative medical solution. Unlike most medical centers where patients are moved to various departments based on what procedures are being performed, the hybrid approach allows patients to be treated in a single OR suite that includes state-of-the-art vascular imaging technology. A well-designed hybrid OR suite allows for vascular imaging, implanting small devices such as stents, devices and open-heart surgery to be performed in the same setting using a single vascular X-ray system, making a hybrid OR extremely efficient for patients and physicians, alike.

Beyond the potential patient benefits of non-surgical intervention, performing multiple procedures, both hybrid and traditional, using



Dr. Hijazi is using the Infinix CF-i/BP to perform a percutaneous procedure.



Dr. Hijazi and his team are using the Infinix CF-i/BP in the hybrid approach while transmitting live via satellite to an educational meeting.

a single hybrid OR suite is extremely cost-effective for the hospital. By performing multiple types of procedures in a single OR suite, the hospital's space and imaging technology are better utilized. Additionally, in the event that a patient undergoing non-surgical intervention requires emergency surgery, the hybrid OR



For information, please call 1-800-BRAUN2 (227-2862)

[www.bbraunusa.com](http://www.bbraunusa.com)



Working Together to Develop a Better Tomorrow

***“In order to make the hybrid approach successful, a state-of-the-art interventional vascular X-ray system must serve as the foundation of any hybrid OR suite.”***

room is already sterile and equipped with the proper tools and technology needed for the clinical staff.

### Common Hybrid Procedures

When performing hybrid procedures, unparalleled access to the patient for the interventional cardiologist, cardiovascular surgeon and other clinical staff is critical for success. Many of the hybrid cases performed at Rush Center for Congenital and Structural Heart Disease include muscular ventricular septal defects and Hypoplastic Left Heart Syndrome (HLHS).

For infants born with HLHS, we can use hybrid intervention to temporarily correct the condition without the patient being put on cardiopulmonary bypass. Going through a median sternotomy, the cardiovascular surgeon bands the left and right branch pulmonary arteries. This is followed by the interventional cardiologist completing a stent implantation in the ductus arteriosus. In a case where the atrial septal communication is restrictive, a stent is placed across the patent foramen ovale, either percutaneously or via a per atrial route.

This hybrid approach for HLHS is far less strenuous for the infant than bypass surgery, which would require the infant's heart to be supported by a machine. After hybrid intervention on HLHS is completed, the infant can grow larger and stronger for several months before the more comprehensive stage II (Norwood and Glenn) procedure is needed.

### Factors to Consider When Creating a Hybrid OR Suite

In order to make the hybrid approach successful, a state-of-the-art interventional vascular X-ray system must serve as the foundation of any hybrid OR suite. The vascular X-ray system must be dependable, produce high-quality images and most importantly, must provide access for the entire clinical team to work together around the patient without compromising quality, efficiency or safety. To maximize the hybrid OR suite, we use it to perform both hybrid interventional and traditional X-ray vascular procedures.

At Rush Center for Congenital and Structural Heart Disease, we use the Toshiba Infinix™ CF-i/BP and have been very pleased with its capabilities. The system provides crisp images and

amazing views, especially when we perform hybrid intervention. The design of the Infinix CF-i/BP makes it ideal for performing hybrid procedures on pediatric and adult patients. The five-axis system allows movement of the C-arm and lateral detectors away from the head of the table, which creates 180 degrees of open access at the head of the table, providing better access for anesthesia, echo and procedures performed from the neck and upper chest area. Its design also enhances collaboration between clinicians and critical equipment used to aid diagnosis and treatment. Since some of these procedures are performed on infants, we use the high-definition flat panel detector to see contrast, dynamic resolution and visualization of small details, such as infant blood vessels.

Along with other leaders in hybrid intervention, I have used the Infinix CF-i/BP to perform live pediatric cases at educational conferences, including Pediatric Interventional Cardiac Symposium (PICS) and the Hybrid Approach to Congenital Heart Disease (ISHAC) symposium for hundreds of clinicians via live satellite transmission. Rush Center's hybrid OR suite is equipped with state-of-the-art broadcasting equipment to continue our commitment to advancing education of pediatric patient treatment. These conferences bring together international faculty to provide demonstrations, live operations and the latest breakthroughs in interventional cardiology for congenital heart disease.

Centers including Nationwide Children's Hospital in Columbus, Ohio, led by my colleague John P. Cheatham, MD, and Rush Center for Congenital and Structural Heart Disease have experience in hybrid intervention for HLHS and are dedicated to continuing to refine this innovative approach to improve patient outcomes. Centers looking to establish their own hybrid approach using a hybrid OR suite may consider collaborating with well-established centers with proven track records, such as the teams at Nationwide Children's or Rush Center, to learn first-hand about the hybrid approach and the patient care that follow.

**See a live case at the Hybrid OR Suite at RUSH Center for Congenital and Structural Heart Disease**  
[www.chdvideo.com/videos/HybridORSuite/index.html](http://www.chdvideo.com/videos/HybridORSuite/index.html)

CCT

Ziyad M. Hijazi, M, MPH  
 Director  
 Rush Center for Congenital and Structural Heart Disease  
 Rush University Medical Center  
 1653 W. Congress Parkway  
 Kellogg Building  
 7th Floor, Suite 708  
 Chicago, IL 60612 USA  
 Phone: 312-942-6800; Fax: 312-942-5360

[ziyad\\_hijazi@rsh.net](mailto:ziyad_hijazi@rsh.net)



Barth Syndrome  
 Foundation

## The Barth Syndrome Foundation

P.O. Box 974, Perry, FL 32348

Tel: 850.223.1128

[info@barthsyndrome.org](mailto:info@barthsyndrome.org)

[www.barthsyndrome.org](http://www.barthsyndrome.org)

**Symptoms:** Cardiomyopathy, Neutropenia, Muscle Weakness, Exercise Intolerance, Growth Retardation

## Medical News, Products & Information

### Digisonics Unveils Cardiac Cath Imaging and Reporting Capabilities at ACC 2009.

Digisonics showcased their new DigiView Cath package for the first time at this year's ACC meeting in Orlando, FL.

DigiView Image Management & Reporting System, the #1 KLAS ranked Cardiology PACS system\*, is vendor-neutral with standards-based, multi-modality reporting and a single database. The newly introduced catheterization module interfaces with patient registration, hemodynamics, and radiographic systems, ensuring a seamless workflow. DigiView's robust database allows users to quickly derive valuable departmental statistics for accreditation and research purposes including extraction of ACC NCDR-compliant data sets.

DigiView's flexible tools were designed with the physician in mind. The integrated, touch sensitive screen and drawing pen allow physicians to quickly identify and label the location of stenosis, stents, and clots on the customizable coronary diagrams. Physicians can use their own preferred coronary artery map, or the system-provided left-dominant and right-dominant maps. Beyond annotation of coronary diagrams, the system also provides quantitative coronary artery analysis with automatic edge detection.

Upon finalization, cardiac cath reports can be automatically transmitted to an integrated EMR/EHR, HIS, RIS and/or PACS system.

With DigiNet Pro, users will have fully functional remote access to the complete cardiovascular image management and reporting system, including the new cath capabilities, from virtually anywhere, at anytime via the web.

For further information, please contact: [www.digison.net](http://www.digison.net).

\*Digisonics DigiView, 2008 Top 20 Best in KLAS Awards: Software & Professional Services, [www.KLASresearch.com](http://www.KLASresearch.com).

### Test Successfully Identifies Life-Threatening Heart Condition

Newswise — A study led by investigators at Beth Israel Deaconess Medical Center (BIDMC) has demonstrated that a new immunohistochemical test is reliable in diagnosing a dangerous arrhythmic heart disease known as arrhythmogenic right ventricular cardiomyopathy (ARVC). Reported in the March 12, 2009 issue of *The New England Journal of Medicine* (NEJM), the new findings offer the possibility of a highly sensitive and specific means of

identifying this life-threatening condition at an early stage, when it can be treated with by implanting a cardiac defibrillator.

"In many individuals, ARVC has no symptoms or warning signs, meaning that the first and only manifestation of disease is sudden death," explains the study's senior author Jeffrey E. Saffitz, MD, PhD, Chairman of the Department of Pathology at BIDMC and Mallinckrodt Professor of Pathology at Harvard Medical School. The hereditary condition, which affects approximately 1 in 5,000 individuals worldwide, is particularly prevalent among Mediterranean populations and, in Italy, is the leading cause of sudden cardiac death among patients under age 35.

ARVC affects the muscle of the heart's right ventricle (one of the organ's two main pumping chambers) so that, over time, muscle cells become replaced by fatty deposits and fibrosis, leaving the right ventricle especially susceptible to arrhythmias. Once an arrhythmia develops, the heartbeat becomes rapid and erratic causing the victim to grow dizzy or collapse -- and in the most serious cases to suffer sudden cardiac death.


"ARVC has been linked to genetic mutations in proteins that form desmosomes, subcellular structures responsible for cell-to-cell adhesion," explains Saffitz, whose laboratory studies connections between cells in the heart and their relationship to arrhythmias and sudden cardiac death. Several years ago, he and his colleagues discovered that a desmosomal protein known as plakoglobin was dramatically diminished in tissue samples of ARVC. In this new study, the authors set out to determine if this reduced plakoglobin signal could serve as a biomarker for ARVC early in the course of the disease.

After ascertaining that the protein was indeed diminished in cases of ARVC -- and not from other types of heart disease -- the authors performed "blinded" immunohistochemical analysis of heart-biopsy samples, obtained from an ARVC registry located at Johns Hopkins University School of Medicine.

The results were remarkably accurate.

"On the basis of clinical criteria, we made the correct diagnosis in 10 of 11 subjects with definite ARVC and correctly ruled out ARVC in 10 of 11 subjects who did not have the condition," explains Saffitz. "There was no question that the plakoglobin signal level was reduced diffusely in the ARVC samples."

Although previous studies have found that magnetic resonance imaging (MRI), electrocardiography and echocardiography can accurately identify patients with advanced AVRC, these tests are much less sensitive for patients with earlier or less conspicuous disease, notes Saffitz.



# ASE 2009

20th Annual Scientific Sessions  
June 6-10 • Washington, DC

**Dedicated  
Congenital Track!**

"An immunohistochemical test [based on plakoglobin levels] could, in the future, provide clinicians with an important new diagnostic tool," he adds. "Cardiologists at major medical centers in the U.S. routinely evaluate cases of unexplained arrhythmias, and this new test may help them to identify ARVC in some of these patients and to exclude it as a cause of arrhythmias in others.

"Additional work will be necessary to validate this new test but it holds considerable promise in identifying people at risk of sudden death in whom preventive measures such as placement of an internal defibrillator may be life-saving," says Saffitz.

BIDMC has filed patents covering methods of diagnosing ARVC.

This study was supported by grants from the March of Dimes, the British Heart Foundation, the Heart Rhythm Society, the National Institutes of Health, the Lerner Fund, the Bogle Foundation, St. Jude Medical Foundation, the Healing Hearts Foundation, the Cassa di Risparmio de Padova e Rovigo Foundation and the British Heart Foundation and United Kingdom National Institute for Health Research Biomedical Research Centres.

Study coauthors include BIDMC researchers: Angeliki Asimaki, PhD (first author) and Shiva Gautam, PhD; Harikrishna Tandri, MD, Hugh Calkins, MD, and Marc Halushka, MD, PhD, of Johns Hopkins Medical Institutions, Baltimore; Hayden Huang, PhD, of Brigham and Women's Hospital; Cristina Basso, MD, PhD and Gaetano Thienne, MD, of the University of Padua Medical School, Italy; Adalena Tsatsopoulou, MD, and Nikos Protonotarios, MD, of Yiannis Protonotarios Medical Center, Naxos, Greece; and William J. McKenna, MD, DSc, of the Heart Hospital, University College London Hospitals National Health Service Trust.

For more information, visit [www.bidmc.org](http://www.bidmc.org).

### Beaumont Hospitals Integrates Cardiology and Radiology Images and Data with IMPAX® from Agfa HealthCare

Agfa HealthCare, a leading provider of IT-enabled clinical workflow and diagnostic imaging solutions, announced that Beaumont Hospitals, Royal Oak, MI will be expanding its current IMPAX® radiology PACS (Picture Archiving and Communication System) to include IMPAX Cardiovascular for imaging and reporting in its cardiology department.

The new cardiology system will include solutions for adult and pediatric echocardiography, cardiac catheterization, and vascular ultrasound. When the installation is completed in 2009, Beaumont will be one of Agfa HealthCare's largest integrated radiology-cardiology PACS site in North America with more than 800,000 radiology and 85,000 cardiology exams annually.

"The Agfa HealthCare IMPAX Cardiovascular system will help support echocardiogram and vascular studies at our hospital, including on-site and remote display of clinical images," says Paul Peabody, Beaumont's CIO. "The system is integrated with the electronic medical records system used throughout Beaumont's patient care network and we plan to implement and integrate the cardiac catheterization module in the future."

Beaumont has one of the world's largest interventional cardiology programs. A leading national center for cardiac research, Beaumont consists of three hospitals in the greater Detroit area.

IMPAX Cardiovascular provides diagnosticians with a single point of access for multi-modality studies and a longitudinal, consolidated view of patient images and information. The open standards-based solution provides image acquisition, display, reporting, storage, and distribution management from multiple cardiovascular imaging modalities, including adult and pediatric echocardiography, vascular ultrasound and angiography, cardiac catheterization, nuclear cardiology, cardiac CT, and ECG.

By consolidating radiology and cardiology studies, Beaumont provides its clinicians with an integrated view of patient data, promoting a confident diagnosis. Patient images and information can be accessed securely from any PC, improving knowledge sharing and distribution of reports between hospital-based and referring physicians. The integrated database solution is easy to manage and promotes cost savings.

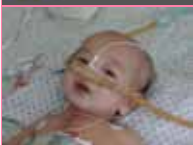
For more information on Agfa HealthCare, please visit [www.agfa.com/healthcare](http://www.agfa.com/healthcare).

### Recently Identified Genetic Heart Disorder Often Deadly For Young Patients

Newswise — A study that included young patients with a recently recognized rare type of cardiomyopathy linked to a genetic mutation finds that progression of this disease may be rapid, and often results in early death, according to a study in the March 25, 2009 issue of *JAMA*.

Mutations in the lysosome-associated membrane protein gene (LAMP2; known as Danon disease) produce a cardiomyopathy in young patients that clinically is similar to severe hypertrophic cardiomyopathy (HCM; a condition in which the heart muscle becomes thick, making it harder for blood to leave the heart, forcing the heart to work harder to pump blood). However, the natural course of Danon disease has been unclear, according to background information in the article.

Barry J. Maron, MD, of the Minneapolis Heart Institute Foundation, Minneapolis, and colleagues assessed the natural history associated with LAMP2 cardiomyopathy and the outcomes of diagnostic and management strategies. The study



### VOLUNTEER YOUR TIME!

We bring the skills, technology and knowledge to build sustainable cardiac programmes in developing countries, serving children regardless of country of origin, race, religion or gender.

[www.babyheart.org](http://www.babyheart.org)

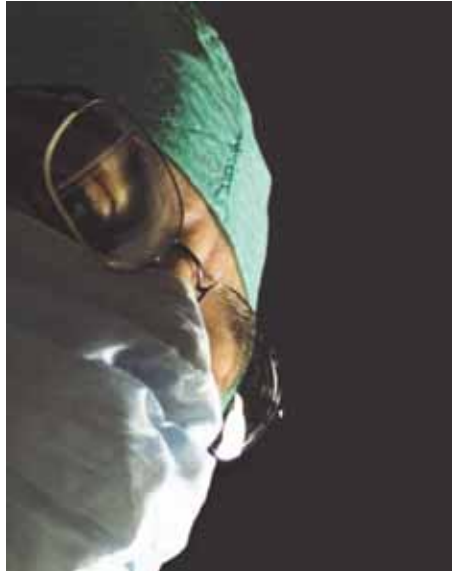included seven patients (six boys) who were ages 7-17 years at the time of diagnosis with LAMP2 mutations. Clinical diagnosis in six patients occurred as a result of a heart murmur, family screening and findings on routine electrocardiogram (ECG) or by symptoms (chest pain or fainting) and, in one patient, by atrial fibrillation (abnormal heart rhythm).

During the subsequent average time of 8.6 years after diagnosis, each of the seven patients experienced serious adverse clinical consequences by 14 to 24 years of age (average, 21 years). Four patients died of acute or progressive heart failure, and one patient underwent heart transplantation. Clinical deterioration was often rapid, with the time interval from clinical stability with little or no symptoms to end-stage heart failure as brief as 6 months. Two other patients experienced sudden unexpected major arrhythmic events, with one patient dying suddenly (age 14 years) from ventricular fibrillation (very rapid, uncoordinated contractions of the ventricles) that was not responding to implantable cardioverter-defibrillator (ICD) therapy.

All seven patients developed left ventricular systolic (contraction of the left ventricle) dysfunction. All patients had received ICDs, which ultimately failed to terminate lethal ventricular tachyarrhythmias (an excessively rapid heartbeat accompanied by an irregular heartbeat) in five patients. The most recent echocardiographic studies obtained of the patients demonstrated marked left ventricular hypertrophy (enlargement) in each. Postmortem examination of two hearts showed massive cardiac hypertrophy.

"The clinical course of these seven patients with LAMP2 mutations provides important insights regarding molecular diagnosis as well as the natural history, pathophysiology, and clinical implications of this recently recognized genetic cardiomyopathy. LAMP2 mutations cause a particularly profound and accelerated cardiac disease process characterized by clinical deterioration and early death, perhaps representing one of the most lethal cardiomyopathies in young and usually male patients. Such an outcome occurred in the patients in our study despite application of the most contemporary treatment strategies, including the ICD ..." the authors write.

"The early experience with the distinctive natural history and prognosis of patients with LAMP2 mutations establishes the importance of molecular diagnosis and underscores the utility of genetic testing."



## Need to Recruit a Pediatric Cardiologist?

Advertise in Congenital Cardiology Today, the only monthly newsletter dedicated to pediatric and congenital cardiologists.

Reach the most Board Certified or Board Eligible pediatric cardiologists throughout the U.S. and Canada.

Recruitment advertising includes full color in either the North American print edition or the electronic PDF International edition.

Available in 1/3 and 1/2 page vertical Recruitment ad sizes. We can even create the ad for you at no extra charge!

### For more information contact:

Tony Carlson, Founder  
**CONGENITAL CARDIOLOGY TODAY**  
 Tel: +1.301.279.2005  
[TCarlsonmd@gmail.com](mailto:TCarlsonmd@gmail.com)

© 2009 by Congenital Cardiology Today (ISSN 1554-7787-print; ISSN 1554-0499-online). Published monthly. All rights reserved.

### Headquarters

9008 Copenhaver Dr. Ste. M  
 Potomac, MD 20854 USA

### Publishing Management

*Tony Carlson, Founder & Editor*  
[TCarlsonmd@mac.com](mailto:TCarlsonmd@mac.com)  
*Richard Koulibanis, Publisher & Editor-in-Chief*  
[RichardK@CCT.bz](mailto:RichardK@CCT.bz)  
*John W. Moore, MD, MPH, Medical Editor/*  
*Editorial Board*  
[JMoore@RCHSD.org](mailto:JMoore@RCHSD.org)

### Editorial Board

Teiji Akagi, MD  
 Zohair Al Halees, MD  
 Mazeni Alwi, MD  
 Felix Berger, MD  
 Fadi Bitar, MD  
 Jacek Bialkowski, MD  
 Philipp Bonhoeffer, MD  
 Mario Carminati, MD  
 Anthony C. Chang, MD, MBA  
 John P. Cheatham, MD  
 Bharat Dalvi, MD, MBBS, DM  
 Horacio Faella, MD  
 Yun-Ching Fu, MD  
 Felipe Heusser, MD  
 Ziyad M. Hijazi, MD, MPH  
 Ralf Holzer, MD  
 Marshall Jacobs, MD  
 R. Krishna Kumar, MD, DM, MBBS  
 Gerald Ross Marx, MD  
 Tarek S. Momenah, MBBS, DCH  
 Toshio Nakanishi, MD, PhD  
 Carlos A. C. Pedra, MD  
 Daniel Penny, MD  
 James C. Perry, MD  
 P. Syamasundar Rao, MD  
 Shakeel A. Qureshi, MD  
 Andrew Redington, MD  
 Carlos E. Ruiz, MD, PhD  
 Girish S. Shirali, MD  
 Horst Sievert, MD  
 Hideshi Tomita, MD  
 Gil Wernovsky, MD  
 Zhuoming Xu, MD, PhD  
 William C. L. Yip, MD  
 Carlos Zabal, MD

### FREE Subscription

Congenital Cardiology Today is available free to qualified professionals worldwide in pediatric and congenital cardiology. International editions available in electronic PDF file only; North American edition available in print. Send an email to [Subs@CCT.bz](mailto:Subs@CCT.bz). Include your name, title, organization, address, phone and email.

### Contacts and Other Information

For detailed information on author submission, sponsorships, editorial, production and sales contact, current and back issues, see website or send an email to: [INFO@CCT.bz](mailto:INFO@CCT.bz).



# PICS-AICS 09

Pediatric and Adult Interventional Cardiac Symposium

JUNE 21-23, 2009  
CAIRNS  
AUSTRALIA

AT THE 5th WORLD CONGRESS OF PAEDIATRIC CARDIOLOGY AND CARDIAC SURGERY (WCCPCS)

[www.picsymposium.com](http://www.picsymposium.com)

## Course Directors:

*Dr. Ziyad M. Hijazi, Dr. William Hellenbrand, Dr. John P. Cheatham, Dr. Carlos Pedra, and Dr. Geoffrey K. Lane*

## Course Co-Director:

*Dr. Zahid Amin*

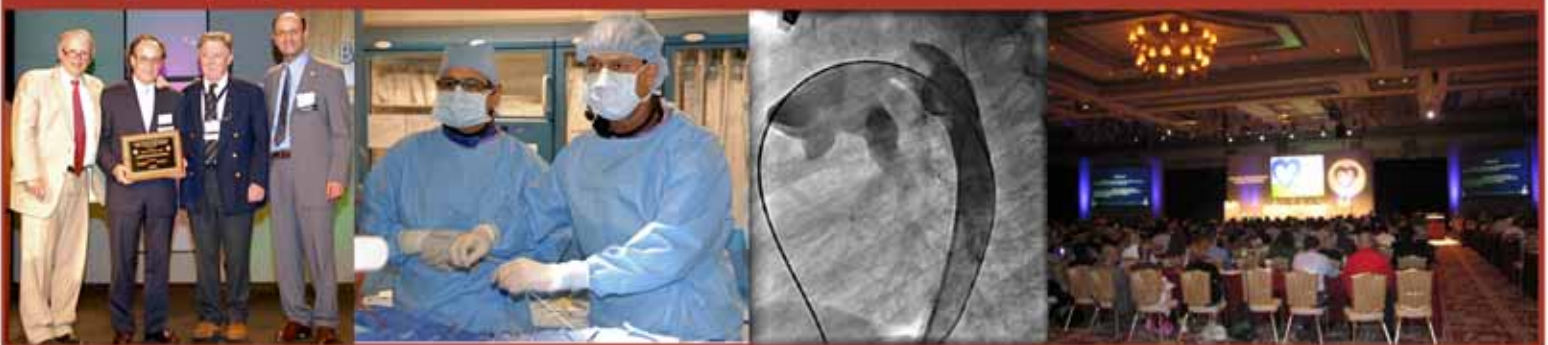- **FOCUSING ON THE LATEST ADVANCES IN INTERVENTIONAL THERAPIES FOR CHILDREN AND ADULTS** with congenital and structural heart disease, including the latest technologies in devices, implantable valves, stents and balloons. Special sessions will provide an in-depth focus on septal defect closure, coarctation stenting, embolization therapies, emerging new imaging modalities for cardiac intervention, and hybrid intervention for HLHS.
- **BREAKOUT SESSIONS** for all professionals who work in Pediatric and Adult Cardiology, the catheterization lab and operating room.
- **HOT DEBATES** between cardiologists and surgeons on controversial issues on intervention for congenital and structural heart disease.
- The popular session "**MY NIGHTMARE CASE N THE CATH LAB.**"
- **LIVE CASE DEMONSTRATIONS** from multiple international venues featuring approved and non-approved devices will be transmitted daily from many cardiac centers around the world. During these live cases, attendees will have the opportunity to interact directly with the operators to discuss the management options for these cases.
- **ACCREDITATION** - CME accreditation will be available. Please see the PICS website for detailed information.
- **ABSTRACTS** - Interventional abstracts will be presented at the World Congress meeting June 22-26, 2009.

## REGISTRATION INFORMATION

This year's PICS-AICS meeting will take place June 21-23, 2009 in Cairns, Australia. PICS-AICS is a sub specialty meeting of the World Congress meeting. For more information go online to: [www.picsymposium.com](http://www.picsymposium.com)



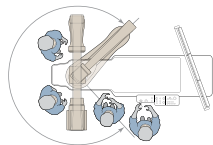
[www.picsymposium.com](http://www.picsymposium.com)





## The smallest lives often need the greatest access.

*(Our Infinix™-i cath lab provides room to operate on the smallest anatomy.)*



The slender c-arms of our Infinix-i cath lab positioners were built with design input from leading pediatric clinicians, not just engineers in faraway laboratories. Those arms are intricate mechanisms that articulate into optimal positions, yet are simple enough to be driven with one hand. They can be maneuvered in the perfect place, out of the way but right where your team needs them for the best possible access to the patient. Discover how Infinix-i can provide the room you need to operate. Get more details at [www.medical.toshiba.com](http://www.medical.toshiba.com).

