



## Table of Contents

- 1 **An Exciting Story of the Boy with Tetralogy of Fallot**  
*Jacek Bialkowski, MD & Malgorzata Szkutnik, MD*
- 6 **Matters of The Heart and Mind: A Matter of Two Minds and Two Hearts**  
*Neil Wilson, MBBS, DCH, FRCPCH, FSCAI*
- 8 **Kids MoD PAH: Mono- vs. Duo-Therapy for Pediatric Pulmonary Arterial Hypertension**  
*Lewis Romer, MD*
- 9 **Book Review – Getting Better: A Doctor's Story of Resilience, Recovery and Renewal**  
*John W. Moore, MD, MPH*
- 10 **Medical News**
  - Fabric Genomics Partners with Intermountain Children's Health to Enhance Precision Diagnosis of Infants and Children Using Whole Genome Sequencing from Broad Clinical Labs
  - First Dual-Chamber Leadless Pacemaker Implanted in a Child
  - Robotic Arm-Based, 5G-Enabled Remote Echocardiograms Show High Diagnostic Accuracy
  - New Device for Transcatheter Aortic Valve Replacement Improves Survival and Reduces Complications for Heart Patients
  - Trametinib Shows Promise in Treating Severe Hypertrophic Cardiomyopathy in Children
- 16 **Meeting Calendar**  
**Career Opportunities Throughout**

## An Exciting Story of the Boy with Tetralogy of Fallot

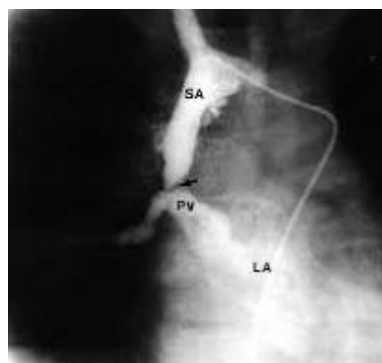
*Jacek Bialkowski, MD & Malgorzata Szkutnik, MD*

Many years ago, a short article was published about an 11-year-old boy, including an angiogram showing a connection between the right subclavian artery and the right upper pulmonary vein.<sup>1</sup> Severe stenosis at the anastomotic site had protected the right lung from high pressure (**Figure 1**). Now, we would like to present the complete story of this patient, recognizing the contributions of a chain of well-meaning individuals.

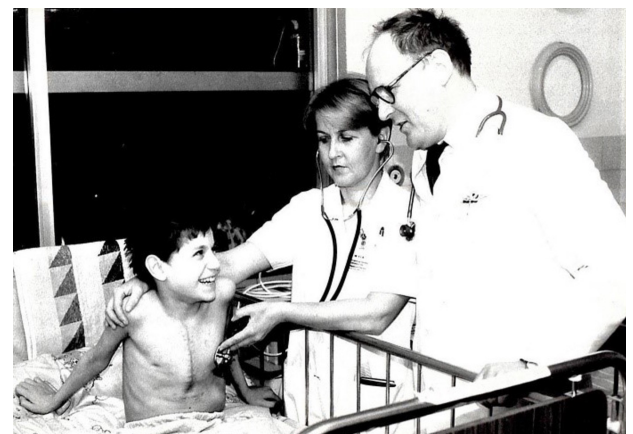This patient was first evaluated by Dr. Michal Wojtalik, a Pediatric Cardiac Surgeon from our hospital, the Silesian Center for Heart Diseases in Zabrze, Poland. In 1995, Dr. Wojtalik had been working in Tbilisi, Georgia, helping establish a cardiac surgery program for Congenital Heart Diseases. There, he encountered a 10-year-old orphan (Wlodek) with a complex cyanotic heart defect. Determining that surgery on-site was unfeasible, he arranged for the child's transfer to Zabrze. One of the authors (JB) was officially designated by Georgian authorities as the child's legal guardian.

The patient's medical history revealed that he had undergone surgery in Moscow six years earlier, where an attempt was made to create a Blalock-Taussig-Thomas shunt. In Zabrze, Dr. Szkutnik performed preoperative catheterization, which confirmed a diagnosis of Tetralogy of Fallot and identified the unusual shunt (as described above). On December 12, 1995, Dr. Wojtalik performed corrective surgery, closing the anomalous shunt and completing the total correction. However, a significant residual ventricular septal defect (VSD) persisted. Although the boy remained stable, he continued to experience circulatory insufficiency. Efforts to return him to Georgia or find an adoptive family in Poland proved challenging, and our surgeon declined to attempt a second surgery. His stay at our hospital lasted nearly a year (**Figure 2**).

Our hospital's director urged me (JB) to secure sponsorship for the costs of his treatment. Eventually, we received financial support from Pope John Paul II, to whom



**FIGURE 1** Angiography Connection of right subclavian artery with the right upper pulmonary vein - black arrow indicates stenosis



**FIGURE 2** Wlodek in the Silesian Center for Heart Diseases in Zabrze, Poland, with Drs. Magda Kowalska and Jacek Bialkowski



## TABLE OF CONTENTS

### 1 An Exciting Story of the Boy with Tetralogy of Fallot

Jacek Bialkowski, MD & Malgorzata Szkutnik, MD

### 6 Matters of The Heart and Mind: A Matter of Two Minds and Two Hearts

Neil Wilson, MBBS, DCH, FRCPC, FSCAI

### 8 Kids MoD PAH: Mono- vs. Duo-Therapy for Pediatric Pulmonary Arterial Hypertension

Lewis Romer, MD

### 9 Book Review – Getting Better: A Doctor’s Story of Resilience, Recovery and Renewal

John W. Moore, MD, MPH

### 10 Medical News

- Fabric Genomics Partners with Intermountain Children’s Health to Enhance Precision Diagnosis of Infants and Children Using Whole Genome Sequencing from Broad Clinical Labs
- First Dual-Chamber Leadless Pacemaker Implanted in a Child
- Robotic Arm-Based, 5G-Enabled Remote Echocardiograms Show High Diagnostic Accuracy
- New Device for Transcatheter Aortic Valve Replacement Improves Survival and Reduces Complications for Heart Patients
- Trametinib Shows Promise in Treating Severe Hypertrophic Cardiomyopathy in Children

### 16 Meeting Calendar

Career Opportunities Throughout



## ONO<sup>®</sup> Retrieval Device

Plan beyond what was previously in reach with the ONO Retrieval Device. This enabling technology is designed to receive, align, compress and remove material from the vascular system.

Plan Beyond.

For more information or to place an order, contact your B. Braun Interventional Systems Representative or call 877-836-2228.





Children's Hospital Colorado



Affiliated with  
University of Colorado  
Anschutz Medical Campus

## Follow Your Heart at Children's Hospital Colorado

The Children's Hospital Colorado Heart Institute's goal is simple: to improve the quality of life for all patients with congenital and childhood heart conditions. We do this by bringing together multidisciplinary experts, innovative research and advanced procedures. Join us in this work to help us make a meaningful difference for children and families through expert and compassionate care.

**700+**

Heart surgeries  
performed annually

**90+**

Cardiologists and advanced  
practice providers

**20+**

Outreach locations, spanning  
four states and 1000+ miles

### OPEN POSITIONS

#### Medical Director, Single Ventricle Program

The inaugural Medical Director of the Single Ventricle Program will provide leadership of established single ventricle outpatient clinics and will be encouraged to develop a vision for how to optimize and advance the inpatient transition of single ventricle patients across all surgical stages.

##### About our program:

- Team includes six physicians, two advanced practice providers and a dedicated nurse coordinator
- Home to Complex Congenital Heart Disease Clinic for interstage patients with a home-monitoring program and Single Ventricle Continuity Clinic for patients stage 2 and beyond
- Fontan Multidisciplinary Clinic that includes expertise in pediatric and adult congenital heart disease cardiology, hepatology, pulmonology, neuropsychology and nutrition
- 96.7% Norwood survival rate

#### Medical Director, Heart Institute Quality And Safety

The Medical Director of Quality and Patient Safety will provide overall leadership of quality improvement and patient safety initiatives in the Heart Institute. This strategic leadership role will collaborate with the Chief of Cardiology, Cardiovascular Surgery and hospital and quality/safety nursing leadership to create sustainable plans for inpatient and outpatient teams in clinical effectiveness and patient and team member safety.

##### About our program:

- Robust partnerships with the cardiothoracic surgical team
- Monthly, multidisciplinary morbidity and mortality conferences
- ELSO Platinum Center of Excellence and only ECMO program in the region
- Core site for the Pediatric Heart Network, together with Washington University



To apply, please contact:

**SHELLEY MIYAMOTO, MD**

Co-Director, Heart Institute, Children's Hospital Colorado  
Chair, Pediatric Cardiology, University of Colorado School of Medicine



Shelley.Miyamoto@childrenscolorado.org





FIGURE 3 Pope John Paul II with our patient

we expressed our gratitude during a visit to Rome (Figure 3). Having collaborated previously with Wilhelmina Children’s Hospital in Utrecht, the Netherlands, on surgeries for Polish children with congenital heart defects, we sent the boy’s complete medical documentation, including catheterization films, to Utrecht. There, he was deemed eligible for another surgery (offered free of charge). Following the procedure, his condition improved, though a significant residual VSD remained.

Meanwhile, a Polish family living in Germany adopted the boy. We consulted with colleagues — including Dr. Charles E. Mullins (Houston, USA), Dr. Ramon Bermudez Canete (Madrid, Spain), and Dr. Luigi Ballerini (Rome, Italy) — regarding the possibility of a percutaneous VSD closure. They advised that a second surgery by an expert surgeon would be the best option due to the shunt’s location. Dr. Marc R. de Leval in London agreed to take on the case, performing a successful operation.

The boy’s health stabilized, though he developed a right bundle branch block (RBBB) with a wide QRS complex, for which beta-blockers were prescribed. Tragically, at age 17, he suffered a sudden cardiac arrest at home, leading to severe

neurological injury despite resuscitation. He lived in a medical shelter in Germany, receiving respiratory therapy and care from his adoptive family. I (JB) visited him twice, and he recognized me with joy. He passed away at the age of 23. In conclusion, arrhythmias and sudden death are serious late complications for patients following Tetralogy of Fallot repair.<sup>2</sup>

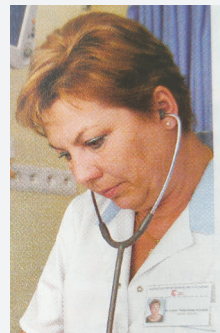## References

1. Sreeram N, Henneveld H, Hitchcock JF. An unusual palliative shunt for cyanotic congenital heart disease. *Heart* 1997;78(4):342, doi: 10.1136/hrt.78.4342.
2. Gatzoulis MA, Balaji S, Webber SA, et al. Risk factors for arrhythmia and sudden cardiac death late after repair of tetralogy of Fallot: A multicentre study. *Lancet* 2000;356(9234):975-81, doi: 10.1016/S0140-6736(00)02714-8.



### JACEK BIALKOWSKI, MD

*Professor & Emeritus Chief of Pediatric Cardiology and Congenital Heart Defects Department*  
FMS in Zabrze, Medical University of Silesia, Silesian Center for Heart Diseases Zabrze, Poland  
[jabi\\_med@poczta.onet.pl](mailto:jabi_med@poczta.onet.pl)



### MALGORZATA SZKUTNIK MD

*Professor & Emeritus Chief of Catheterization Laboratory of Pediatric Cardiology and Congenital Heart Defects Department*  
FMS in Zabrze, Medical University of Silesia, Silesian Center for Heart Diseases Zabrze, Poland  
[jabi\\_med@poczta.onet.pl](mailto:jabi_med@poczta.onet.pl)

## Publish

- Written by fellows, doctors and their team
- Case studies, articles, research findings, reviews and human interest
- No publication fees
- Print and electronic
- Published within 3-6 months of submission
- Fellows: turn PowerPoint decks into articles



CONGENITAL  
CARDIOLOGY  
TODAY



Subscribe Electronically  
Free on Home Page

[www.CongenitalCardiologyToday.com](http://www.CongenitalCardiologyToday.com)



## Associate / Assistant Level Congenital Interventional Cardiologist - Pediatric Cardiology

Join the University of Maryland School of Medicine, Department of Pediatrics, Division of Pediatric Cardiology. As we grow our signature pediatric heart program, we are seeking Assistant and Associate level candidates to join a senior established Congenital Interventional Cardiologist as a second interventional cardiologist. Newly graduated fellows as well as early to mid-career I.C.s are welcome to apply.

The successful applicant must have a MD or MD and PhD degrees, or their equivalent. Candidates should have clinical training in Pediatrics and Pediatric Cardiology (completed fellowship and be board eligible or board certified). Preference will be given to candidates who have expertise in interventional cardiology and either fetal imaging or general cardiology.

### Position Highlights:

- Superb working environment including 10 physicians and a commensurate group of NPs
- Collaborate with experts, including a world renowned pediatric cardiac surgeon, genetics, behavioral pediatrics and pediatric neurology and board certified adult congenital cardiologists
- Excellent collaborative research and leadership opportunities
- Strong inpatient and outpatient cardiology practice to include nine practice sites across the State of Maryland

### Features:

- Full spectrum of care from prenatal and birth to childhood and adulthood, all in one hospital
- **BRAND NEW!** State of the art Bi-Plane Philips Cath Lab configured for a full spectrum of procedures in pediatric congenital and adult congenital cardiac diagnostic and interventional procedures
- **Full Pediatric Cardiac Anesthesia support**
- State of the art 52-bed Level IV NICU- currently a **U.S. News & World Report top 50 ranked Neonatal ICU**
- 19 bed PICU
- 6 bed IMC
- 29 full service general pediatric beds
- 20 bed Pediatric Emergency Department

### Benefits/Perks:

- Very generous leave package
- Dependent tuition remission for any school within the University of Maryland system
- Excellent pension/retirement plans
- Very competitive salary with bonus opportunity
- Call schedule not more than 1 in 8
- Cath

The University of Maryland Children's Hospital (UMCH) has a renowned Children's Heart Program with dedicated cardiac PICU beds. We have recently expanded our critical care, neurology, and neonatology services providing opportunities for career development. We are also home to a pioneering artificial blood clinical research program.

We are located near the downtown Inner Harbor area, just one of Baltimore's many outstanding attractions. From fine arts and orchestras to professional sports teams, first-class dining and shopping to a wealth of historical sites, our city offers a full range of recreational and cultural opportunities. Washington, D.C., Philadelphia and New York City are within easy reach, as well as beaches to the east and mountains to the west. Educational excellence abounds, as do family-friendly neighborhoods and urban living options. Visit us online at [www.ummsphysician.jobs](http://www.ummsphysician.jobs) to learn more.

Applicants should apply online:

<https://umb.taleo.net/careersection/jobdetail.ftl?job=210001JO&lang=en>  
(Position Number: 03-314-498)

UMB is an equal opportunity/affirmative action employer. All qualified applicants will receive consideration for employment without regard to sex, gender identity, sexual orientation, race, color, religion, national origin, disability, protected Veteran status, age, or any other characteristic protected by law or policy.



**Nicklaus  
Children's  
Hospital**

Where Your Child Matters Most

## Director of Fetal Cardiology & Pediatric Cardiologist, Fetal Specialty

As the **Director of Fetal Cardiology** in Miami, FL, you will lead a dedicated team in providing exceptional care to expectant mothers and their unborn babies facing complex cardiac conditions. This role offers a unique opportunity to make a difference in the lives of families by providing advanced diagnostic and therapeutic interventions for fetal heart abnormalities. The candidate is expected to have demonstrated clinical excellence and leadership success in their career. Additionally, this leader will uphold unwavering integrity and adherence to ethical standards. [Click to apply.](#)

We are also hiring a passionate **BC/BE Pediatric and Fetal Cardiologist** to join our team in Palm Beach County, FL. The ideal candidate will have a strong desire to develop a community-based general pediatric cardiology practice with an emphasis on fetal cardiology. The candidate would collaborate with local hospitals and neonatology practices and provide personalized services to pediatricians, family practice providers, and maternal-fetal medicine specialists in these communities, with a focus on growing the practice within the region. [Click to apply.](#)

Nicklaus Children's Hospital Heart Institute is a renowned center of excellence dedicated to providing world-class cardiac care to pediatric patients. With state-of-the-art facilities and a multidisciplinary team of experts, we deliver comprehensive, compassionate, and cutting-edge care to children with congenital and acquired heart conditions. The Heart Institute offers a wide range of services including the management of patients requiring complex congenital heart surgery, interventional catheterization, invasive electrophysiology, non-invasive imaging (fetal and cardiac MR/CT) and preventive cardiology. Our pediatric cardiology and cardiovascular surgery services are ranked among the nation's best for pediatric cardiology and heart surgery by U.S. News & World Report.

Competitive compensation and benefits package.

**Qualified candidates please contact:**

**Joyce Berger**

Physician Recruiter

[Joyce.Berger@nicklaushealth.org](mailto:Joyce.Berger@nicklaushealth.org)

786.624.3510

**Danyal Khan, MD**

Interim Chief, Cardiology

Nicklaus Children's Hospital Heart Institute

[Danyal.Khan@nicklaushealth.org](mailto:Danyal.Khan@nicklaushealth.org)

[NicklausChildrens.org/NCPS](http://NicklausChildrens.org/NCPS) DFW



# Matters of The Heart and Mind: A Matter of Two Minds and Two Hearts

Neil Wilson, MBBS, DCH, FRCPCH, FSCAI

Oliver Ormerod (RIP) was the best sort of Oxford colleague. He was a deeply committed and talented doctor who, in addition to his adult cardiological experience, had the ability to mentally conjure up the anatomy and physiology of even complex Congenital Heart Disease. That is unusual in your average adult cardiologist. He naturally gravitated to taking on a large proportion of the adult congenital practice. As if that wasn't enough, he had a deep sense of understanding the impact of Congenital Heart Disease on adults and younger children and their families. I loved working with him as he had great dexterity in the cath lab and a great sense of humour. Together it was a mutually productive existence. I had his help with some bigger patients needing intervention and he had me help him with some of the structural adult cases: paravalve leaks, PFOs, left atrial appendage closure cases when device knowledge was helpful. Typically, it took him about two cases to become familiar and efficient with intracardiac echo. Oliver also did an outpatient clinic with the obstetricians which managed pregnant mothers with Congenital Heart Disease. I didn't have anything per se to do with that, though he used to describe various patients he was perhaps cogitating about as to how to manage their pregnancy. You will realise immediately, taking on managing such a patient means you are managing two patients. Apologies for using the cliché; we all want to quote two hundred percent survival and of course avoid any alternative outcome. See the title.

One morning, between patients during a list of PFO closure using ICE, he discussed with me Denise, a 21-year-old patient with Tetralogy of Fallot-type pulmonary atresia anatomy who had had reparative surgery as a child with a right ventricle to PA homograft and fenestration of the VSD. Enter the interventionists... We had together implanted bilateral PA stents and closed her fenestrated VSD with an Amplatz device when she was 18 and I felt we'd had a very good result. I was half expecting him to voice his concerns about stenosis in those stents. I was wrong (again). His concern was about her depleted right ventricular function and moderate stenosis and regurgitation in the right ventricular homograft. She was advised against pregnancy but this being real life she presented at 16 weeks pregnant and there was now greater concern as she had RV hypertension and RV dilation. Fetal 'wellbeing' was judged as 'reasonable.' So, what would you do? Come on, make a decision.... Our decision was to leave things alone, keep her under close review and hope she gets into the third trimester.

But... at 23 weeks the obstetrician and fetal cardiologist were concerned about fetal growth which was significantly retarded. Additionally, Denise's RV pressure was pushing two-thirds systemic. Now what would you do? We discussed her upside down, inside out, backwards and forwards with the great and the good in let's call them 'Respected' centres. The opinions we got varied from 'Leave it alone' to 'Interventional pulmonary valve replacement with

the Melody Valve.' Two options. Now what would you do? There were split opinions in the department. That didn't make decision-making easy. It was helpful that Steve Westaby, the surgeon, was supportive. You can guess from the title of this piece we did go ahead with the Melody implant three days later. I think we got the Melody to 20mm or so.

We had advice from the medical physics team to reduce radiation exposure (fluoro frame rate 2/second!) and the help of Kate, The Grebenator, a hugely experienced anaesthetist. All went well with a needle to skin and back time well under two hours and an infinitesimally small calculated uterine dose. Phew! I can't remember fluoroscopy time but surely it was very short.

Recovery was uneventful with a rapid improvement in clinical signs and Echo Doppler evidence of a reduction in Denise's RV pressure and RV dimensions. At 30 weeks (we got her into the third trimester!) the obstetric team were comfortable that the fetus was small but growing acceptably.

Real life remember.... Then two weeks later.... Denise went into labour.... with an unfavourable uterine artery pattern (not that I would know what that is). Unfavourable enough for a Caesarian section delivery of a 1.5kg baby in good shape, resuscitation not necessary. Well, perhaps it was for Oliver and me. Oliver had spent much of the day of delivery (including in the OR for the C Section) at Denise's bedside. I confess the following evening we did have a resuscitative beer ourselves. On many occasions since then we debated between ourselves. Did we make the right decision? We got the baby eight weeks in utero and delivered in good shape. Her postnatal growth was stellar. Mom stayed well and further intervention was not needed. Or perhaps we just got lucky? Maybe things would have turned out fine anyway. Two hundred percent survival. You be the judge.

Oliver sadly didn't survive. He died two years ago of pancreatic cancer. The hospital isn't the same. I miss him very much.



**NEIL WILSON, MBBS, DCH, FRCPCH, FSCAI**

*Formerly Professor of Pediatrics  
University of Colorado School of Medicine  
Formerly Director Cardiac Catheter Laboratory  
Children's Hospital Colorado  
Colorado, USA  
[Neilwilson1955@icloud.com](mailto:Neilwilson1955@icloud.com)*





Join the PICS Society in

# CHICAGO

AUGUST 25-28, 2025

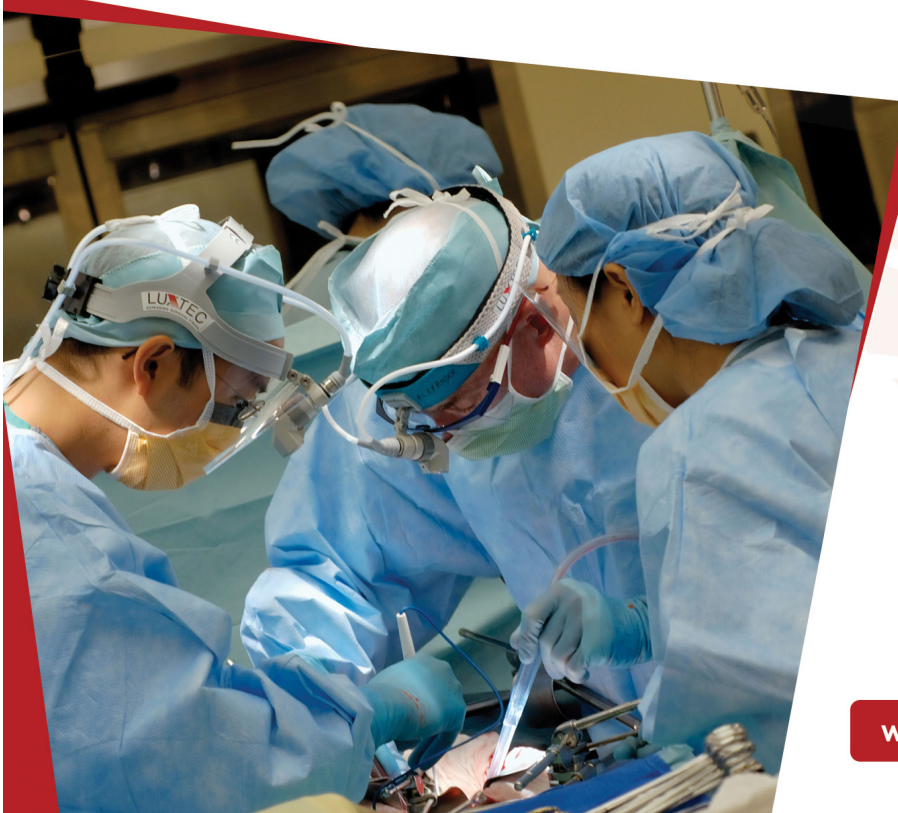MARRIOTT MARQUIS CHICAGO

**SAVE  
THE  
DATE**



## CONGENITAL CARDIOLOGY TODAY

Timely News & Information for Congenital/Structural Cardiologists & Cardiothoracic Surgeons Worldwide



### Recruitment Advertising

- ✓ In print and electronic monthly issue
- ✓ On our website
- ✓ In monthly Email Blast
- ✓ No cost for CCT to create the ad
- ✓ Multiple sizes available



Subscribe Electronically  
Free on Home Page

[www.CongenitalCardiologyToday.com](http://www.CongenitalCardiologyToday.com)



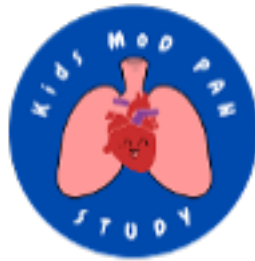# Kids MoD PAH: Mono- vs. Duo-Therapy for Pediatric Pulmonary Arterial Hypertension

Lewis Romer, MD

## Importance of the Study

Pediatric pulmonary arterial hypertension (PAH) is a severe and often progressive disease. Despite the availability of targeted drugs for PAH in adults, data regarding the use of these agents remains extremely limited for children. There is also a lack of multicenter randomized clinical trials in this area. This results in off-label use of PAH medications and uncertainties of optimal clinical endpoints for such studies in children.

The Kids MoD PAH study aims to address this disparity in clinical evidence by conducting a Phase III randomized, open-label trial. This trial will compare the safety and efficacy of first line combo therapy (sildenafil + bosentan) to first line monotherapy (sildenafil alone) in 80 newly diagnosed, treatment naive pediatric participants enrolled at 15 North American PPHNet Consortium Centers (Pediatric Pulmonary Hypertension Network).



## Study Description

**Study Design:** Phase III, Randomized, Open-Label, Pragmatic, Superiority Trial

**Study Duration:** 5 years

**Duration of Study Participation:** 24 months

**Study Population:** 80 newly diagnosed, treatment naive pediatric participants ages 3 mos-18 years with WSPH Group 1 or 3 pulmonary arterial hypertension (PAH) and WHO FC II or III symptoms

**Study Intervention:** Sildenafil monotherapy vs. sildenafil + bosentan dual therapy

**Primary Endpoint:** WHO FC at twelve months after initiation of study drug therapy

**Secondary Endpoints:** Time to clinical worsening; WHO FC at twenty-four months, PK and safety of study drug(s), ECHO metrics of right ventricular pressure and function,  $\delta$ MWD for subjects 8+ years of age, serum NT-proBNP levels

**Exploratory Endpoints:** Actigraphy metrics, QoL, biomarkers

## Key Inclusion Criteria

- Not treated with long-term standing PAH drug therapy
- Diagnosis of PAH by cardiac catheterization within the previous six months or ECHO for infants under one year of age

- Age  $\geq$ 3 months to < 18 years
- WSPH groups 1 or 3, and Current WHO FC II or III

## Key Exclusion Criteria

- RV Failure
- Syncope, overt RV failure, cyanotic “spells” or systemic hypotension within four weeks of enrollment
- Evidence of diffuse or focal pulmonary venous disease
- Left- sided heart functional disease
- CHD (other than PDA) repaired within six months of enrollment
- Inability to take oral medications as prescribed

## Principal Investigators

CCC: Erika Berman Rosenzweig, MD (New York Medical College), Steven Abman, MD (University of Colorado), and Lewis Romer, MD (Johns Hopkins University)

DCC: Hirshikesh Chakraborty, DrPH (Duke University), Kanecia Zimmerman, MD (Duke University), and Gayane Yenokyan, PhD (Johns Hopkins University)

[ClinicalTrials.gov/](https://clinicaltrials.gov/) NCT04039464 FUNDED BY: NHLBI

Interested in learning more, please contact:  
Lewis Romer, MD at [lromer@jhmi.edu](mailto:lromer@jhmi.edu) or visit  
<https://kidspahtrial.org/>



**LEWIS ROMER, MD**

*Professor, Anesthesiology and Critical Care Medicine  
Cell Biology, Biomedical Engineering, and Pediatrics, Center for Cell Dynamics  
Johns Hopkins University School of Medicine, Charlotte R. Bloomberg Children's Center  
Baltimore, MD, USA*

[lromer@jhmi.edu](mailto:lromer@jhmi.edu)





# Getting Better: A Doctor's Story of Resilience, Recovery and Renewal

By Andrew G. Kadar, MD (published 2024)

John W. Moore, MD, MPH

"On numerous other occasions, I had stood at the same desk looking for information on my patients. This time in an unwelcome role reversal, I was directed to get on a gurney. Behind a curtain, I removed my surgical scrubs and put on a patient gown.... I placed my clothes and doctor's ID badge in a plastic bag labeled with my name and the inscription, PERSONAL BELONGINGS.... Lying on a gurney, as a patient, I felt awkward, out of place, uncomfortable, naked, vulnerable, and embarrassed...." So, Dr. Andrew Kadar described his transition from doctor to patient status, beginning his new life as a heart patient.

Kadar was a practicing anesthesiologist at Cedars-Sinai Medical Center, a well-known heart hospital in Los Angeles, California. Well-trained, experienced, and respected by his colleagues, he led a disciplined and wholesome life. He was careful about his diet, exercised regularly, and was blessed with family longevity. Although married late in life, he looked forward to having a family with his wife, Rachel.

His whole existence abruptly changes when he is 62-years-old. He starts feeling strong chest pains during exercise routines. When these symptoms become undeniable, he submits to cardiology consultation and testing. He receives bad news. Intervention won't work, he needs open-heart surgery. Broadly speaking, his surgery is successful. Kadar, who initially is confused and distraught, finds strength and resolve to undergo recovery and rehabilitation. Eventually, he resumes his professional and personal life, with a new status and a new vulnerability.

He peppers his story with explanations of medical terms, disease processes, and medical procedures such that it is easily understandable by lay readers. In addition, Kadar continuously places his experiences in context by providing numerous contemporary, historical, and literary references regarding many aspects of his journey.

Through his personal story, Dr. Kadar shares a unique perspective as both physician and patient while he faces a major health problem and his mortality, both for the first time. He walks the reader through denial of symptoms, hesitancy to submit to definitive evaluation, vulnerability, embarrassment, and guilt he feels as a patient, the trauma of surgery, and the prolonged and arduous physical, emotional, and spiritual aspects of his recovery. After many months, he returns to work as an

anesthesiologist, becomes a parent, and ten years later retires from practice.

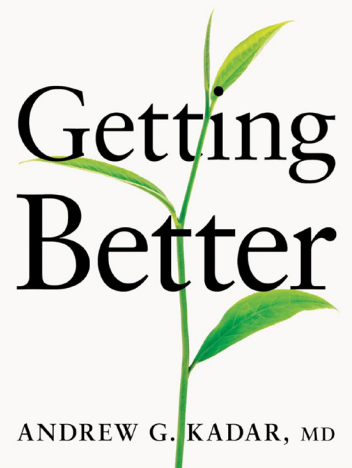Kadar publishes this book when he is 74-years-old. He is more reflective than he was prior to the surgery:

*Since my heart surgery, I think more about how I spend my time and how what I do impacts others. I compliment people more often, to make sure they know that their good deeds elicit appreciation and gratitude. I am more focused and determined to make a positive impact on my family, friends, and community. As a result, at least in some ways, this difficult interlude has also made my life better....*

This memoir is a must read for physicians and health care workers. All of us who care for sick heart patients, often with a good deal of compartmentalization and denial, inevitably will confront our own serious illnesses and mortality. It helps to learn from a colleague's experience. There are important lessons and messages for us in this book.



A DOCTOR'S STORY OF RESILIENCE,  
RECOVERY, AND RENEWAL



**JOHN W. MOORE, MD, MPH**

*Emeritus Professor of Pediatrics,  
UC San Diego School of Medicine  
Director of Cardiology,  
Rady Children's Hospital (2006-2021)  
Medical Editor, Congenital Cardiology Today  
San Diego, CA, USA  
[jwmmoore1950@gmail.com](mailto:jwmmoore1950@gmail.com)*



# Fabric Genomics Partners with Intermountain Children's Health to Enhance Precision Diagnosis of Infants and Children Using Whole Genome Sequencing from Broad Clinical Labs

Fabric Genomics, the leader in artificial intelligence (AI)-powered next generation sequencing interpretation, is announcing a new partnership with Intermountain Children's Health to analyze the whole genomes of children sequenced by the Broad Clinical Labs to help speed diagnosis of kids who may have genetic diseases.

This collaboration is a milestone in helping children facing critical health challenges and receiving care in inpatient and outpatient care settings, starting at Intermountain Primary Children's Hospital in Salt Lake City, a renowned leader in pediatric healthcare and the flagship pediatric hospital for Intermountain Health. The sample-to-report genome service enables healthcare professionals to identify genetic disorders with unprecedented speed and precision and to tailor treatment plans to the unique genetic makeup of each infant.

Offered by partners Broad Clinical Labs and Fabric Genomics, the sample-to-report genomic analysis service makes whole genome sequencing (WGS) and diagnosis accessible to healthcare systems who may not currently have genomics infrastructure and expertise in-house.

Intermountain Primary Children's Hospital has long been a pioneer in innovation, striving to deliver the highest standard of care for its young patients. The partnership between Broad Clinical Labs and Fabric Genomics addresses the critical need for affordable, accurate genomic insights, particularly for infants undergoing surgical repair of congenital heart disease (CHD).

This new service also offers competitive pricing and fast turnaround times that will help Intermountain keep costs low, while increasing the quality and quantity of data for better diagnoses.

"We are excited to integrate the Broad Clinical Labs' whole genome sequencing service and Fabric's Enterprise software platform into the clinical workflow within our pediatric cardiac intensive care unit (CICU). It's a game-changer for the children and families we serve," said Martin Tristani-Firouzi, MD, pediatric cardiologist for University of Utah Health and Intermountain Primary Children's Hospital.

"This partnership allows us to quickly and cost-effectively access top-tier, clinical-grade genome sequencing and reporting, more accurate diagnoses for these infants, and the ability to reanalyze the data, all of which ultimately will improve outcomes and enhance the quality of care we deliver to children," Dr. Tristani-Firouzi added. "It also allows us to integrate with our research organization in the Department of Pediatrics at the University of Utah and continuously develop research protocols for unsolved cases."

The WGS service from Broad Clinical Labs utilizes GEM, Fabric's AI algorithm, a highly sensitive, innovative tool that can more

*"Our collaboration with Intermountain Primary Children's Hospital and Broad Clinical Labs is a model for genomic medicine within pediatric healthcare. We look forward to supporting the hospital's medical professionals in their pursuit of precision medicine for these young and vulnerable patients."*

*—Martin Reese, PhD, Co-Founder and CEO of Fabric Genomics*

precisely detect copy number variants (CNVs) and detect causative single nucleotide variants and smaller CNVs that are invisible to commonly used microarray genetic tests. This dramatically broadens the diagnostic space and provides a more complete understanding of the genetic underpinnings of CHD. Fabric's AI also offers opportunities for rapid reanalysis as patient medical histories evolve and knowledge of genetic diseases continues to grow, which adds value for both patients and physicians. The partners are developing protocols to routinely re-analyze cases based on updated phenotype presentations or new database knowledge.

Intermountain is the newest partner and the first healthcare system of the Broad/Fabric offering, which so far includes Nurture Genomics, a newborn sequencing company, and COMBINEDBrain, a non-profit organization dedicated to fast-tracking cures for neurodevelopmental disorders through WGS.





# First Dual-Chamber Leadless Pacemaker Implanted in a Child

Tricia Tomiyoshi

UC Davis Director of Pediatric Electrophysiology, Dan Cortez, MD, has set another world record: He is the first physician to implant a dual-chamber leadless pacemaker in a child. His case report was published this week in the journal *PACE: Pacing and Clinical Electrophysiology*.

A 13-year-old patient was referred to the UC Davis pediatric electrophysiology clinic for presyncope, a feeling of lightheadedness or dizziness without actually fainting, after being monitored for years for congenital complete heart block.

Pacemakers are typically placed in children with congenital complete heart block, a rare condition that can lead to sudden death and affects one in about 15,000 to 22,000 children. Congenital complete heart block may occur due to repaired Congenital Heart Disease or genetic predisposition. It can also be acquired from exposure to certain maternal antibodies.

After serial electrocardiograms and Holter monitors showed progressively lower-than-average heart rates, Cortez talked with the patient and their family about pacemaker options.

Dual-chamber leadless pacemakers help regulate the heart's rhythm by stimulating the heart's upper (atrial) and lower (ventricular) chambers. Because the patient wanted to remain active in sports without restrictions, leadless pacing was presented as an option, and the family agreed.

The AVEIR dual chamber leadless pacemaker was implanted via the patient's same internal jugular vein (instead of the femoral vein) so the patient could move easily and return to sports sooner. The minimally invasive procedure took place in the UC Davis Electrophysiology Lab.

The patient had no complications during or after the procedure. Three months later, the patient was able to resume exercise and play sports.

The AVEIR device is different from traditional pacemakers in part because it has no leads or cords and is absorbed by the heart. It is also 10 times smaller than a traditional pacemaker. This pacemaker has been implanted in adults across the country since it received FDA approval in 2023.

"Everyone, kids included, can now have the benefits of pacemakers without leads and without the complications that come with leads long term," Cortez said. "No matter what kind of pacing a kid needs —atrial or ventricular, or both — they can now safely receive leadless pacing and, after the short recovery period, have no restrictions to their activity level."

*"Everyone, kids included, can now have the benefits of pacemakers without leads and without the complications that come with leads long term."*

*– Dan Cortez, MD, Director of Pediatric Electrophysiology at University of California Davis*



*The AVEIR dual chamber leadless pacemaker. The open hand shows the dual chamber leadless pacemaker, made up of two silver cylinders that look like "AA" batteries.*

In 2023, Cortez was the first physician in the world to implant a retrievable leadless pacemaker in a child. Five years prior to that, Cortez was the first physician in the world to implant a Micra single-chamber leadless pacemaker through the internal jugular vein in a child.







## Pediatric Cardiologist

Springfield, Missouri

The Ward Family Heart Center at Children's Mercy Kansas City seeks a candidate to join our team as a pediatric cardiologist based at our CMKC owned practice in Springfield, MO. The successful candidate would join an existing group of 38 cardiologists (33 in Kansas City, 2 in Springfield, MO, 2 in Wichita, KS, 1 in Topeka, KS), 4 CV surgeons, and over 30 APNs. Experience and interest in outpatient cardiology and outreach is a must. Trainees in their final year are welcome to apply.

Candidates must be board-certified or board-eligible in Pediatric Cardiology. Strong communication skills are key. Salary and academic rank are commensurate with experience.

**Springfield, Missouri** is located in Southwest Missouri and has a rich and diverse history. It was founded in 1829 and is the third most populous city in the State of Missouri. The city has a plentiful and growing job market, great schools, world-class health care, and all the entertainment and cultural options of a big city—but with far less stress and an abundance of character and friendliness. The Springfield, MO based practice is the only pediatric cardiology practice in southwest Missouri, servicing 4 states. This practice sees over 4000 outpatient visits each year across 7 locations.

The Children's Mercy Heart Center serves a population of over 5 million in the heart of the U.S.A. We perform over 500 cardiac operations, 600 cardiac catheterizations including over 200 invasive EP procedures, 18,000 outpatient visits, and more than 20,000 echocardiograms annually. Our two state-of-the-art catheterization labs are both hybrid labs and equipped with the latest 3D imaging and EP technology.

Our Kansas City-based super-specialty resources include Electrophysiology (which includes Clinical EP, pacing and Genetic Arrhythmia), Cardiac Transplantation / Heart Failure, Interventional Cardiology and Advanced Cardiac Imaging (fetal echo, 3D echo, trans-esophageal echo, CT, MRI and 3D printing). We also provide specialized, team-based care in Fetal Cardiology (with on-site delivery services for high-risk neonates in Kansas City), Interstage Monitoring (CHAMP), Preventive Cardiology, Cardiac Genetics, Cardiology, Single Ventricle Survivorship, Pulmonary Hypertension, a dedicated POTS clinic and Cardiac Neurodevelopmental services.

For more information or to apply, submit CV and cover letter using link below, or send to:

[physicianjobs@cmh.edu](mailto:physicianjobs@cmh.edu)  
<https://faculty-childrensmercykc.icims.com/jobs/30486/physician/job>

**Aliessa Barnes, MD**

Co-Director, Ward Family Heart Center;  
 Chief, Section of Cardiology  
 816.983.6225, [apbarnes@cmh.edu](mailto:apbarnes@cmh.edu)

# Robotic Arm-Based, 5G-Enabled Remote Echocardiograms Show High Diagnostic Accuracy

*European Society of Cardiology*

New research presented at the ESC Congress 2024 in London, UK shows that performing echocardiograms remotely using a 5G cellular network has similar accuracy to those performed in person by cardiologists.

Echocardiography is the test-of-choice for the initial evaluation of many cardiac diseases and requires the expertise of a cardiologist for interpretation. However, this expertise is often limited or unavailable in rural or indeed smaller urban areas. Robotic arm-assisted remote echocardiograms have been attempted for teleconsultation in previous studies, but analysis was limited to heart failure patients, primarily due to the network delay in telecommunications and the subsequent inadequate control of the robotic arm equipment.

In this study, the authors assessed the feasibility and diagnostic accuracy of a 5G cellular network and robotic arm-based remote echocardiographic system in an outpatient clinic based 20 kilometres away from Zhongshan Hospital. A total of 51 patients were enrolled from the outpatient cardiology clinic. All underwent standard comprehensive echocardiography on a 5G cellular network, robotic arm-based remote echocardiographic system, as well as a conventional echocardiographic platform (at Zhongshan Hospital) successively.

The order in which patients were examined on the remote and conventional instruments was randomly determined. There was no interval between the two examinations, and examinations of the same patient were performed by experienced but different cardiologists, who were blinded to each other's diagnosis. The doctor who used the remote system was also randomly allocated and had not been previously specifically trained. The examinations were real time and diagnoses were made immediately after the examinations.

From the 51 patients, the image quality was sufficient for diagnosis in 50 patients (24), (48%) female. A single patient was excluded because some key views could not be obtained using the remote system, meaning 98% of the examinations had been technically successful.

Around one-third (17 patients) had a heart problem identified using conventional in person echocardiography, including: 10 with a primary diagnosis of valvulopathy (one Barlow's syndrome, one bicuspid aortic valve and eight less-than-moderate regurgitation), two cardiac surgery follow-ups (one case of aortic valve replacement and septal myectomy, and one case of mitral valve replacement and tricuspid annuloplasty), and two hypertrophy cardiomyopathy (including one case of obstruction at papillary muscle level), two with abnormal left ventricular wall motion (including one case of apical mural thrombus), and one with Congenital Heart Disease (secundum atrial septal defect).

Echocardiograms using the robotic arm resulted in the same diagnosis as conventional in-person echocardiography in 98% of cases (papillary muscle level obstruction was missed in one case).

Time for image acquisition using remote echocardiography was significantly longer (around 50% longer) than conventional (24 mins 36 secs vs. 16 mins 15 secs).

A previous version of the robotic arm has been cleared for clinical use in scanning the abdomen (China, Europe, Australia and Singapore), which requires less complex scanning manoeuvres. However, the authors say a multi-centre study at a larger scale with both other local hospital and referral centres involved should be carried out before this new technology should be used.

Although 5G technology is not available everywhere, lead-author Xianhong Shu, also of Zhongshan Hospital, said: "This system would increase the accessibility of better medical resources as patients may travel less to get diagnosis and medical advice from cardiologists based in referral centres."

She adds there are further potential advantages: "A remote robotic echo system may help protect more health professionals from the risk of exposure during pandemics like the COVID-19 as the cardiologist may not need to be in close contact with the patient if only echocardiogram consultation is required."





# CAREER OPPORTUNITIES

Click the position title to view the full job description

## Pediatric Cardiologist

Banner University  
Medical Center  
Tucson, Arizona



## Pediatric Cardiologist

Loma Linda University  
Children's Hospital  
Loma Linda, California




## Medical Directors

Children's Hospital Colorado  
Aurora, Colorado




## Assist / Assoc Professor of ACHD

Yale University  
School of Medicine  
New Haven, Connecticut



## Assist / Assoc Professor Pediatric Cardiology, Non-Invasive Imaging

Yale University  
School of Medicine  
New Haven, Connecticut



## Medical Director & ACHD Cardiologist

Nemours Children's Hospital  
Wilmington, Delaware



## Director of Fetal Cardiology & Pediatric Cardiologist, Fetal Specialist

Nicklaus Children's Hospital  
Miami, Florida



## ACHD Cardiologist

Louisiana State University  
Children's Hospital of New Orleans (CHNOLA)  
New Orleans, Louisiana



## Pediatric Cardiologist

Tulane University  
Children's Hospital of New Orleans (CHNOLA)  
New Orleans, Louisiana



## Pediatric Cardiologist Advanced Imaging with Cross-Sectional Focus

MaineHealth Maine  
Medical Center  
Portland, Maine



## Assoc / Assist Congenital Interventional Cardiologist

University of Maryland  
Children's Hospital  
Baltimore, Maryland



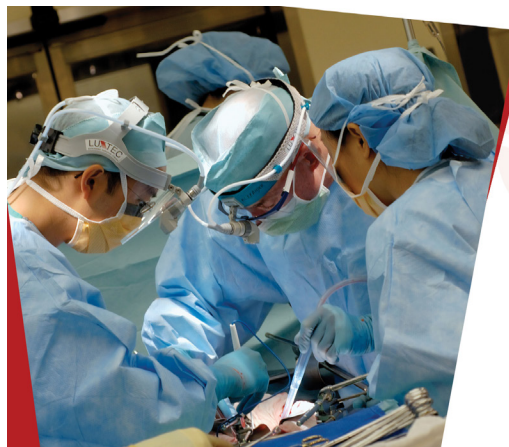## Pediatric Cardiologist

Children's Mercy  
Springfield, Missouri



## Adult Congenital Cardiologist

Akron Children's Hospital  
Akron, Ohio



### Recruitment Advertising

- ✓ In print and electronic monthly issue
- ✓ On our website
- ✓ In monthly Email Blast
- ✓ No cost for CCT to create the ad
- ✓ Multiple sizes available



Subscribe Electronically  
Free on Home Page

[www.CongenitalCardiologyToday.com](http://www.CongenitalCardiologyToday.com)



# New Device for Transcatheter Aortic Valve Replacement Improves Survival and Reduces Complications for Heart Patients

*Mount Sinai-led Study Shows Edwards SAPIEN 3 Ultra RESILIA Valve Can Benefit Younger and Low-surgical-risk Patients*

Transcatheter aortic valve replacement (TAVR), a minimally invasive procedure to replace the aortic valve, performed using the latest-generation SAPIEN 3 Ultra RESILIA valve with the latest-generation leaflet technology and sealing skirt resulted in fewer deaths and fewer complications (leakage around the valve and bleeding) than previous valves. It also had the greatest benefit in low-surgical-risk patients with symptomatic severe aortic stenosis. The results are important considering that younger and lower-risk patients are increasingly undergoing TAVR rather than surgical aortic valve replacement, and a majority of TAVR patients in the United States (more than 60 percent) receive the SAPIEN 3 valve.

This is the first study to report the longest follow-up and one-year outcomes of the SAPIEN 3 Ultra RESILIA valve in one of the largest real-world registries. This study showed that even mild leakage around a balloon-expandable TAVR valve can increase mortality, and that the SAPIEN 3 Ultra RESILIA valve, combined with the latest-generation sealing skirt, leads to less leakage around the valve, which can improve survival. In addition, the new leaflet technology has improved valve hemodynamic performance over its predecessors by having lower gradients and larger openings than before.

Researchers used the US TVT registry to study the one-year outcomes of the latest generation SAPIEN 3 Ultra RESILIA valve and compare them to outcomes of the previous-generation SAPIEN 3 valves.

Researchers compared almost 5,000 patients who got the SAPIEN 3 Ultra RESILIA with almost 5,000 patients with the older SAPIEN 3 and SAPIEN 3 Ultra valves. They also analyzed the SAPIEN 3 Ultra RESILIA with the latest-generation sealing skirt and compared this to SAPIEN 3 with the prior-generation sealing skirt to better understand the one-year outcomes.

\*Both devices are manufactured by Edwards Lifesciences.

At one year post-TAVR, patients in the SAPIEN 3 Ultra RESILIA group had lower rates of all-cause death compared to patients in the SAPIEN 3 / SAPIEN 3 Ultra group (7.6% versus 9.7%). Patients in the SAPIEN 3 Ultra RESILIA group had less leakage around the valve compared to the SAPIEN 3 / SAPIEN 3 Ultra group (15.6% versus 18.5%).

This is the first study to show, that when performing TAVR with balloon-expandable valves, mild or greater leakage around the valve (paravalvular leak) can increase the risk of death within one year after the procedure, so it is imperative to minimize leakage around the valve as much as possible. The latest-generation SAPIEN 3 Ultra RESILIA valve has been found to improve overall one-year survival over its predecessors, driven primarily by less leakage around the valve, while conferring superior hemodynamic performance over prior-generation valves.

This is the first study to show that even mild leakage can impact survival in TAVR. Patients with symptomatic severe aortic stenosis who are candidates for TAVR instead of surgical aortic valve replacement should ask their heart team to see if their anatomy would result in mild or greater leak with the SAPIEN 3 Ultra RESILIA valve platform, which could impact their survival. If their anatomy puts them at risk of mild or greater leakage, surgery should be considered in low-surgical-risk patients.



**CHIP NETWORK**  
CONGENITAL HEART INTERNATIONAL PROFESSIONALS





# Trametinib Shows Promise in Treating Severe Hypertrophic Cardiomyopathy in Children

American College of Cardiology

Trametinib, a mitogen-activated protein kinase (MEK) inhibitor, reduces mortality and morbidity in children with severe hypertrophic cardiomyopathy (HCM) caused by pathogenic variants in the RAS/MAPK pathway, according to a study published in *JACC: Basic to Translational Science*. The study provides strong evidence for personalized treatment targeting the underlying genetic causes of RASopathies, a group of rare disorders that often lead to life-threatening cardiac complications.

HCM, a condition where the heart muscle thickens abnormally, is particularly dangerous in children and can lead to heart failure or premature death. About 20% of patients with RASopathies have HCM; RASopathy-associated HCM is often caused by genetic mutations in the RAS/MAPK signaling pathway, which regulates cell growth and development. It is often a more severe form of HCM and has a higher mortality rate. Until now, treatment options for severe cases of RASopathy-associated HCM (RAS-HCM) in pediatric patients have been limited.

The study, which involved 61 children with severe RAS-HCM, compared 30 children receiving trametinib to 31 children receiving standard care. The results showed a significant reduction in the outcome of death, cardiac transplantation, or the need for cardiac surgery in the trametinib group. No life-threatening adverse events were observed, although dermatologic and mucous membrane side effects were common but manageable.

"This study provides crucial evidence that targeted therapies like trametinib could dramatically improve the outlook for children suffering from severe HCM," Andelfinger said. "It underscores the importance of developing genotype-specific therapies for RASopathies and other rare diseases."

"The paper by Andelfinger and colleagues provides exciting data with respect to treating 'Rasopathies' in children with HCM," said Douglas Mann, MD, FACC, Editor-in-Chief of *JACC: Basic to Translational Science*. "Rasopathies are a group of rare genetic disorders that are caused by mutations in genes that regulate the Ras/mitogen-activated protein kinase (MAPK) signaling pathway."

*"Our findings represent a breakthrough in the treatment of HCM in children, particularly those suffering from severe forms of the disease due to genetic variants in the RAS/MAPK pathway. The positive results we observed with trametinib are a promising step forward in addressing an urgent medical need for children whose condition has not responded to standard therapies."*

*—Gregor Andelfinger, MD, PhD, co-author of the study and cardiologist at CHU Saint-Justine in Montreal*

"Given the rarity of this condition and the lack of existing therapies for these children, we felt it was important to publish this paper, with the hope that it will advance the field by providing a foundation for future randomized clinical trials to definitively evaluate the safety and efficacy of Trametinib in children with HCM," Mann said.

Study limitations include potential biases due to its design and incomplete data collection for the control group. Additionally, the trametinib group included patients with prior heart surgeries, which could affect the results. The shorter follow-up for the trametinib group may also underestimate long-term side effects. Lastly, the study does not determine the optimal dosing of trametinib for RAS-HCM.



**NEONATOLOGY TODAY**  
Peer Reviewed Research, News and Information in Neonatal and Perinatal  
Medicine



## MARCH

08<sup>TH</sup>-11<sup>TH</sup>

CRT25

Washington, DC, USA

<https://crtmeeting.org/>

13<sup>TH</sup>-15<sup>TH</sup>

Cardiology Forum 2025

Kuala Lumpur, Malaysia

<https://cardiologyforum.org/>

29<sup>TH</sup>-31<sup>ST</sup>

Cardiology Forum 2025

Chicago, IL, USA

<https://accscientificsession.acc.org/en>

## MAY

01<sup>ST</sup>-03<sup>RD</sup>

SCAI 2025 Scientific Sessions

Washington, DC, USA

<https://calendar.boomte.ch/single/wA8wW2onbK0H9U1J7mL3ux>

05<sup>TH</sup>-06<sup>TH</sup>

CARDIO 2025 - 4th CME Cardiologists Conference

Istanbul, Turkey

<https://calendar.boomte.ch/single/xA8W2eM6wJ7fk0W2pK0s>

15<sup>TH</sup>-16<sup>TH</sup>

International Conference on Pediatrics and Child Health

Dubai, UAE

<https://calendar.boomte.ch/single/qA8R5uK0dpdtvwU1M6nweH9R5>

## Program Directory 2024-2025

*Published Mid-August*

Directory of Congenital & Pediatric  
Cardiac Care Providers in North  
America

Each program's contact information  
for Chief of Pediatric Cardiology &  
Fellowship Director

Lists each program's  
Pediatric Cardiologists &  
Cardiothoracic Surgeons

Lists Pediatric Cardiology  
Fellowships

Distributed to  
Division Chiefs by mail

Electronic version available on  
CCT's website:

[CongenitalCardiologyToday.com/  
Program-Directory](https://congenitalcardiologytoday.com/Program-Directory)

Need to update your listing?  
Contact Kate Baldwin  
[kate.f.baldwin@gmail.com](mailto:kate.f.baldwin@gmail.com)



**CONGENITAL  
CARDIOLOGY  
TODAY**

**CORPORATE OFFICE**

PO Box 52316  
Sarasota, FL 34232 USA

## CORPORATE TEAM

**PUBLISHER &  
EDITOR-IN-CHIEF**

Kate Baldwin  
*kate.f.baldwin@gmail.com*

**CO-FOUNDER &  
MEDICAL EDITOR**

John W. Moore, MD, MPH  
*jwmmoore1950@gmail.com*

**FOUNDER &  
SENIOR EDITOR**

Tony Carlson  
*tcarlsonmd@gmail.com*

**STAFF EDITOR &  
WRITER**

Virginia Dematatis

**SOCIAL MEDIA  
CONTENT MANAGER**

Jason Williams, MD  
*jason.williams@duke.edu*

**STAFF EDITOR**

Loraine Watts

**EDITOR-IN-CHIEF  
EMERITUS**

Richard Koulbanis

## EDITORIAL BOARD

Aimee K. Armstrong, MD  
Jacek Bialkowski, MD  
Anthony C. Chang, MD, MBA  
Howaida El-Said, MD, PhD  
Ziyad M. Hijazi, MD, MPH  
John Lamberti, MD  
Tarek S. Momenah, MBBS, DCH

John W. Moore, MD, MPH  
Shakeel A. Qureshi, MD  
P. Syamasundar Rao, MD  
Carlos E. Ruiz, MD, PhD  
Hideshi Tomita, MD  
Sara M. Trucco, MD  
Gil Wernovsky, MD

**OFFICIAL NEWS & INFORMATION PARTNER OF**



Statements or opinions expressed in Congenital Cardiology Today reflect the views of the authors and sponsors and are not necessarily the views of Congenital Cardiology Today.

© 2025 by Congenital Cardiology Today LLC  
ISSN 1554-7787 print. ISSN 1554-0499 electronic.  
Published monthly. All rights reserved.